

# Otonomik Gangliyon (GP) Ablasyonu

Dr. Can Hasdemir  
Ege Üniversitesi Tıp Fakültesi

# Atriyal Fibrilasyon Ablasyonu

- Pulmoner Ven İzolasyonu
    - "CFAE" Ablasyonu
    - **GP** Ablasyonu
    - Linear Lezyonlar
      - Rotor Ablasyonu
-

# AF Ablasyonu (Tek İşlem—AARx Yok)

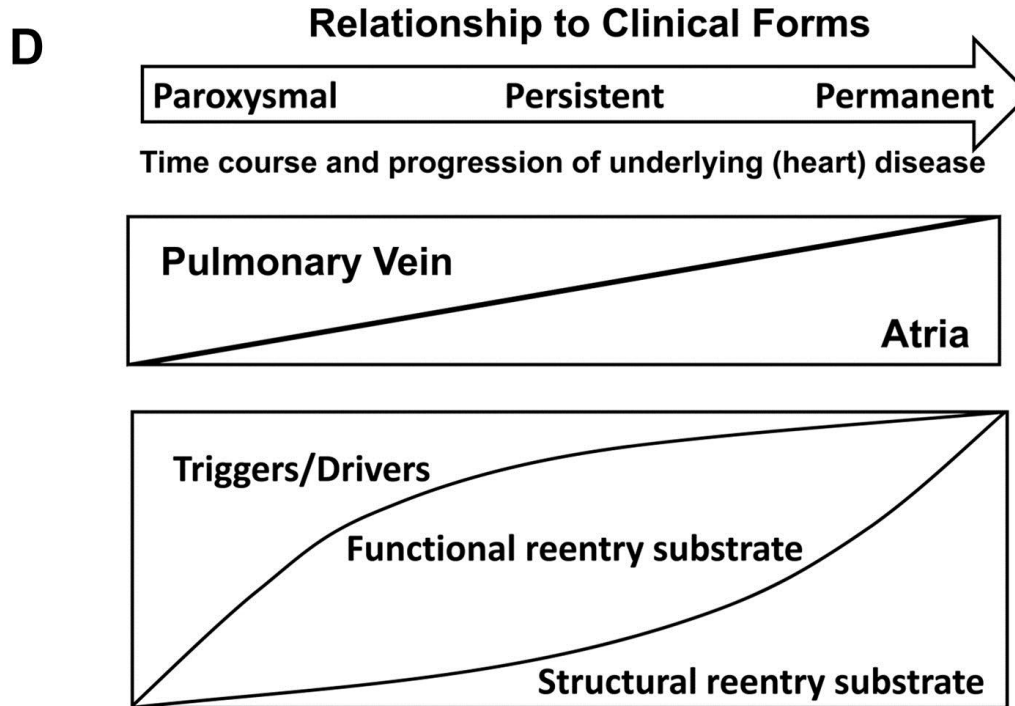
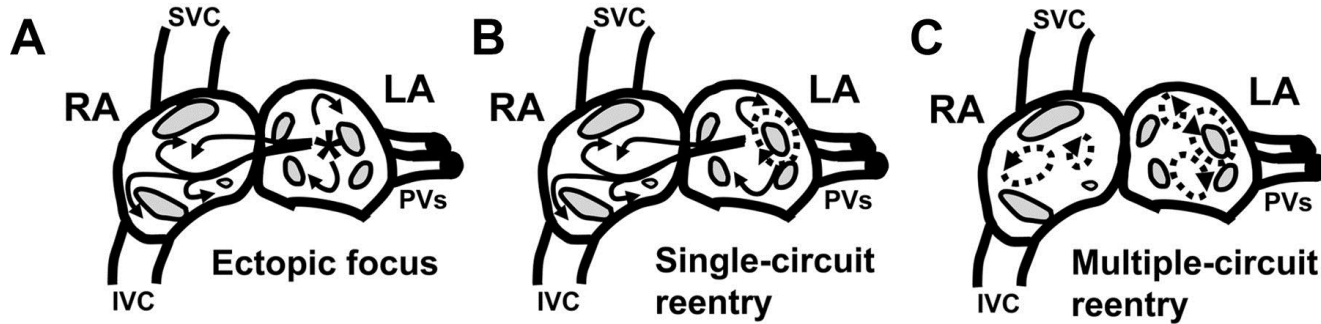
---

- **Uzun dönem başarı oranları düşük:**

- 46% ← - Ouyang F, ve ark. Long-term results of catheter ablation in **paroxysmal atrial fibrillation**: lessons from a 5-year follow-up. Circulation 2010;122:2368-77.
- 49% ← - Medi C, ve ark. Pulmonary vein antral isolation for **paroxysmal atrial fibrillation**: results from long-term follow-up. J Cardiovasc Electrophysiol 2011;22:137-41.
- 29% ← - Weerasooriya R, ve ark. Catheter ablation for atrial fibrillation: are results maintained at 5 years of follow-up? J Am Coll Cardiol 2011;57:160-6.

- **AF mekanizmaları bilinmiyor**

## AF Mechanisms



Iwasaki YK, Nishida K, Kato T, Nattel S. Atrial fibrillation pathophysiology: implications for management. *Circulation* 2011;124:2264-74.

# Atriyal Fibrilasyon Ablasyonu

- Pulmoner Ven İzolasyonu
    - "CFAE" Ablasyonu
    - **GP** Ablasyonu
    - Linear Lezyonlar
      - Rotor Ablasyonu
-

# **Paroksismal Atriyal Fibrilasyon Başlangıcından Önce Sempatik ve Parasempatik Sistem Aktivasyonu**

---

## **Klinik Çalışmalar:**

- Bettoni M, Zimmermann M. Circulation. 2002;105:2753
- Amar D, Kadish A. JACC. 2003;42:1262

## **Temel Çalışmalar:**

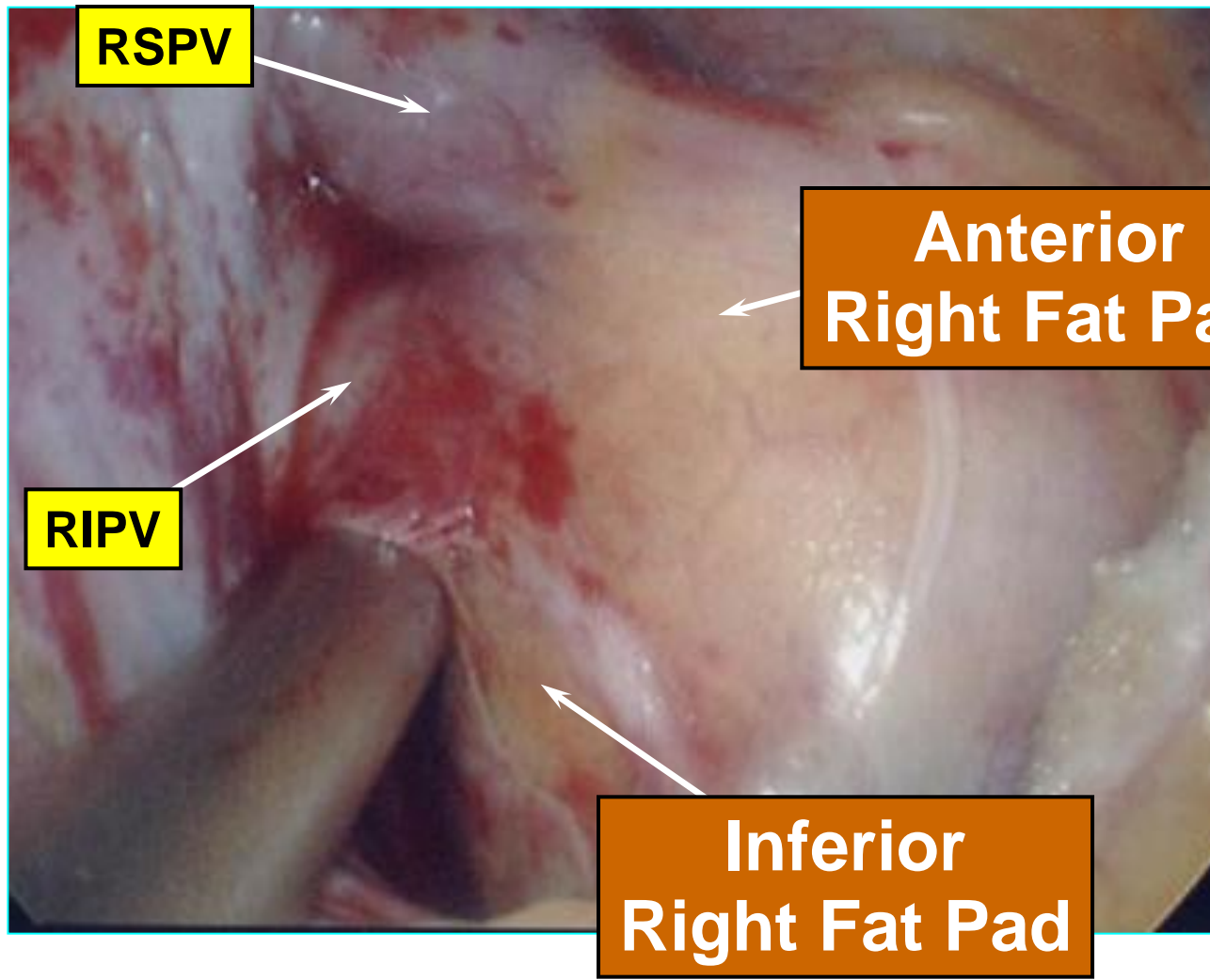
- Ogawa M, Chen PS. JACC 2007;50:335
- Po S, Scherlag BJ. Heart Rhythm 2006;3:201
- Patterson E, Po S. Heart Rhythm 2005;2:624
- Choi EK, Chen PS. Circulation 2010;121:2615

# **Gangliyonlu Pleksus (GP)—Nedir?**

Otonomik Nöral Ağın Bağlantı Merkezleridir

# Right PVs and Ganglionated Plexi

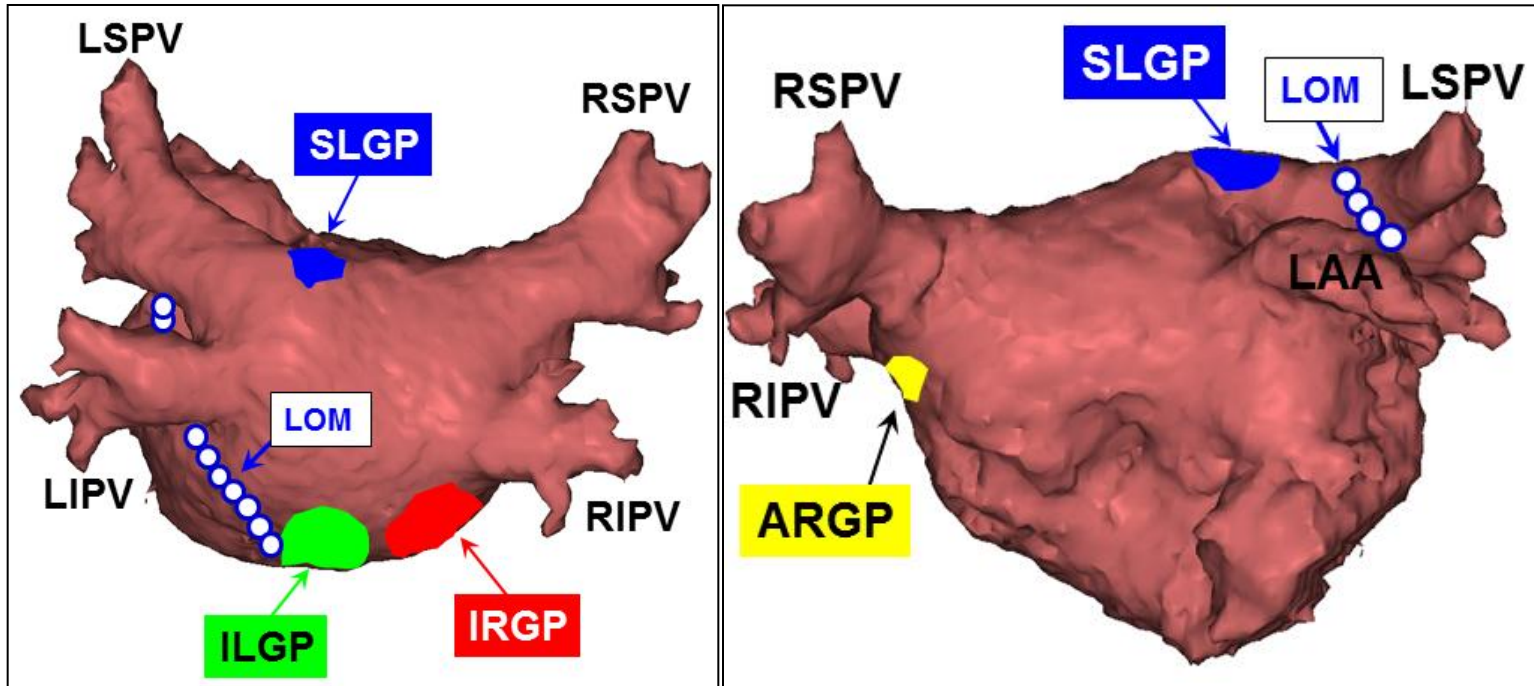
↑  
Head



Foot  
↓

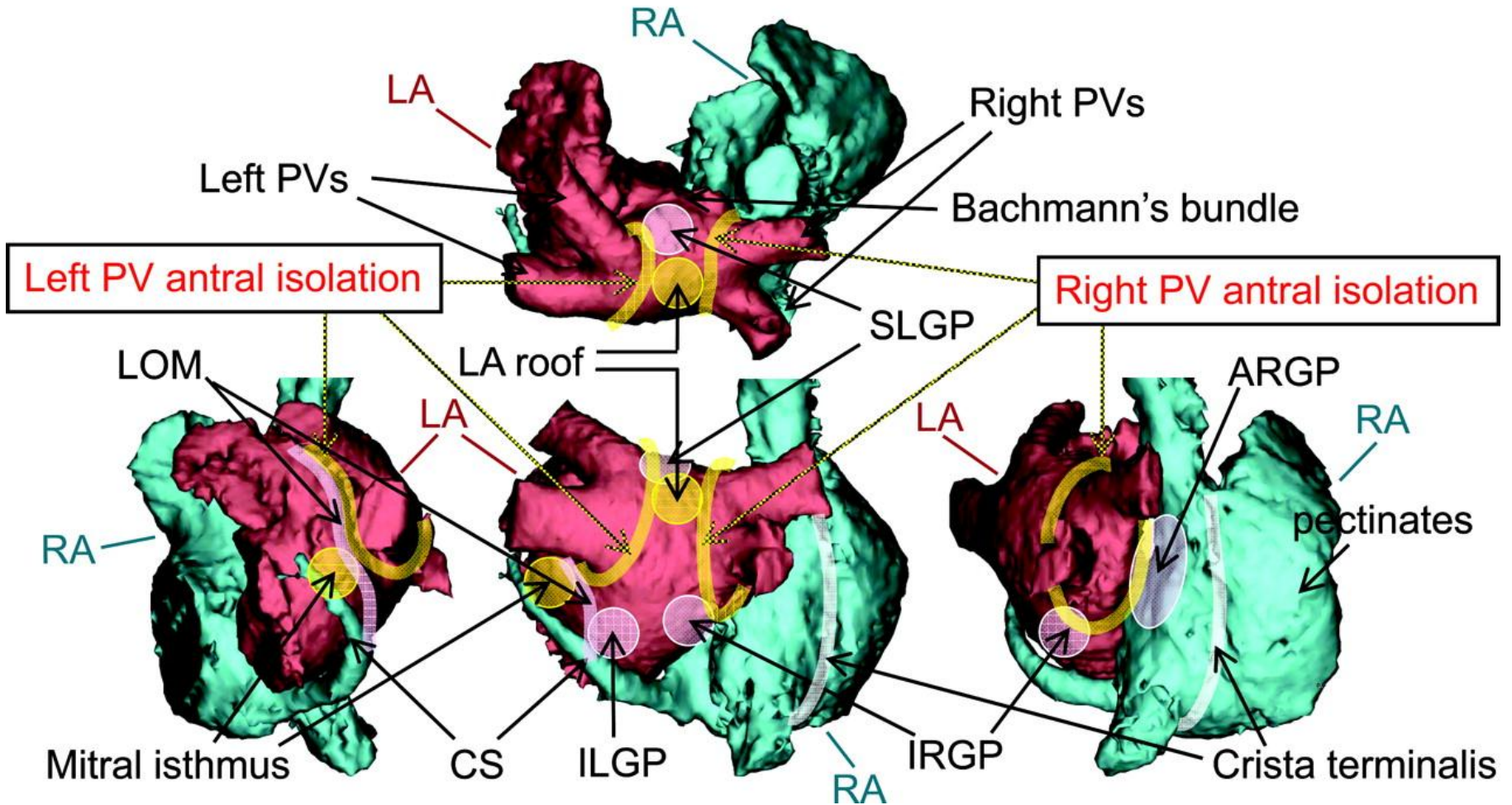


# GP Yerleşimleri



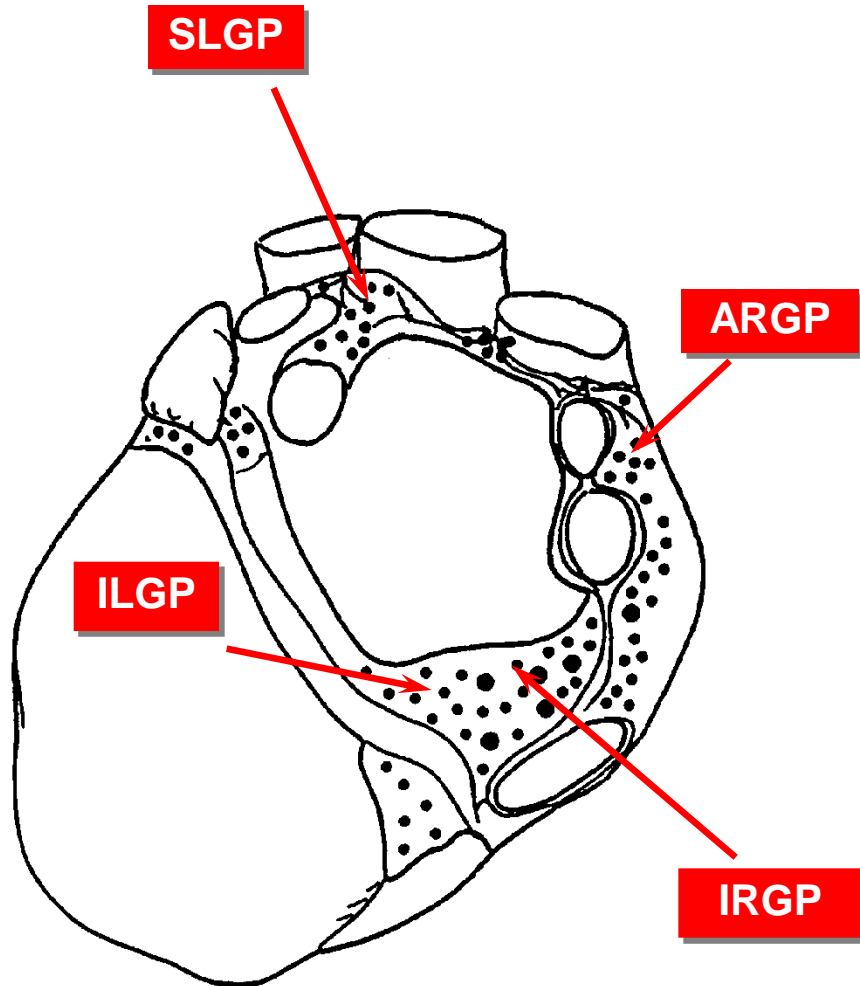
- 1- SLGP
- 2- ILGP
- 3- ARGP
- 4- IRGP
- 5- LOM

# Anatomic factors

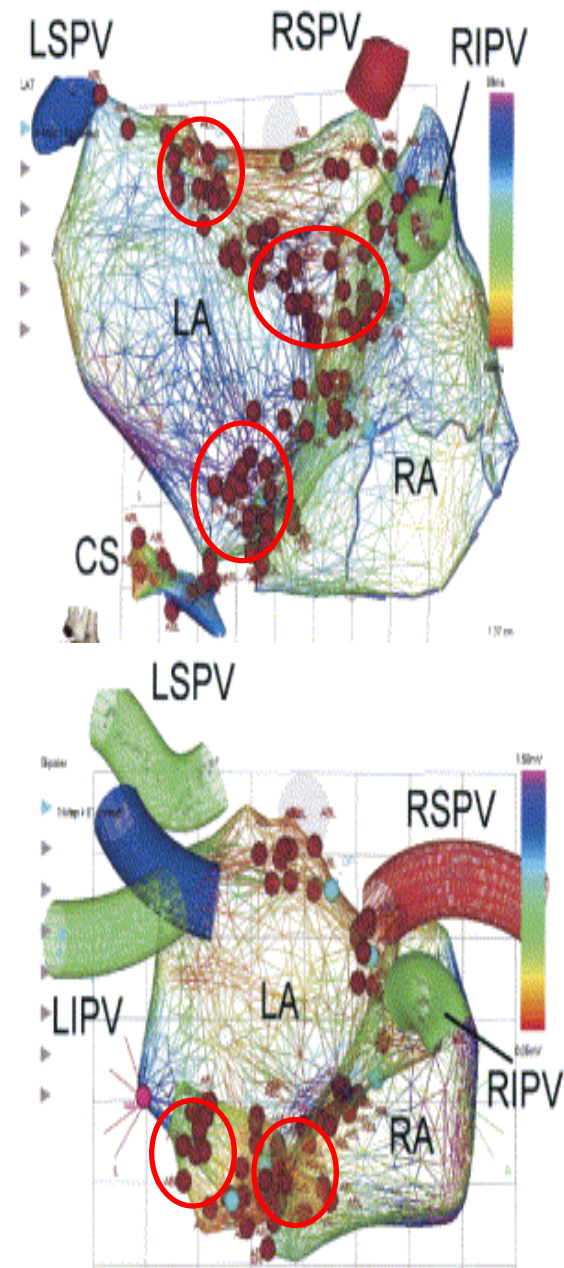


Iwasaki YK, Nishida K, Kato T, Nattel S. Atrial fibrillation pathophysiology: implications for management. *Circulation* 2011;124:2264-74.

# GP ve CFAE Yerleşim Yerleri



Armour JA, ve ark. Gross and microscopic anatomy of the human intrinsic cardiac nervous system. Anat Rec 1997;247:289-98.



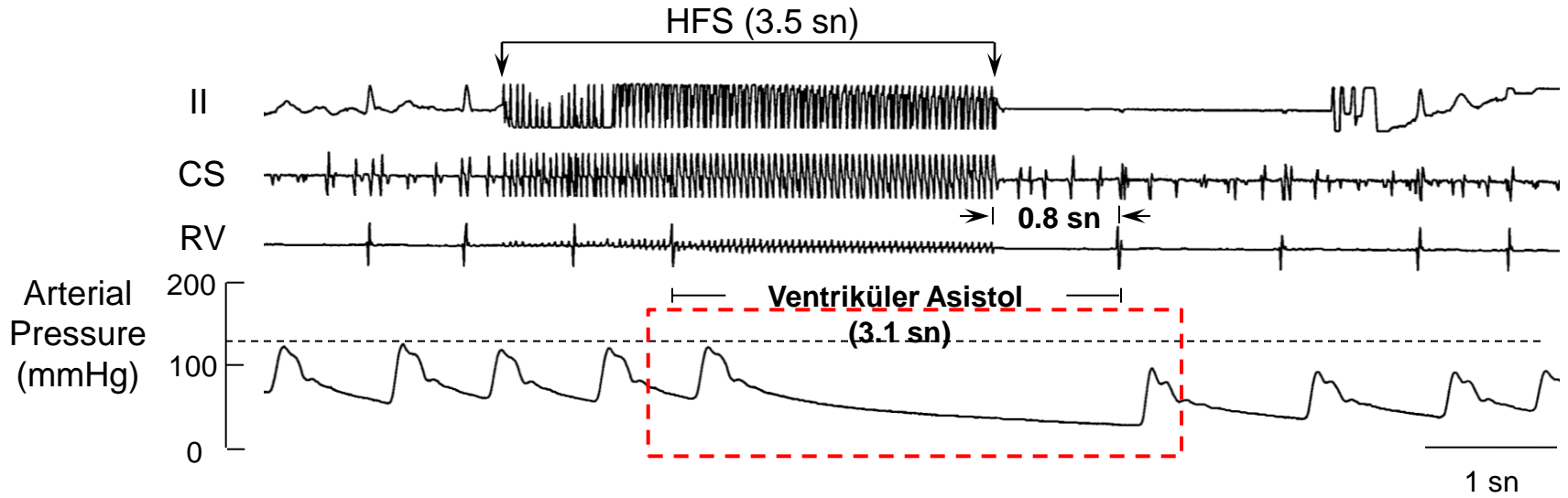
Nademanee K, ve ark. A new approach for catheter ablation of atrial fibrillation: mapping of the electrophysiologic substrate. J Am Coll Cardiol 2004;43:2044-53.

# Yüksek Frekanslı Stimülasyon

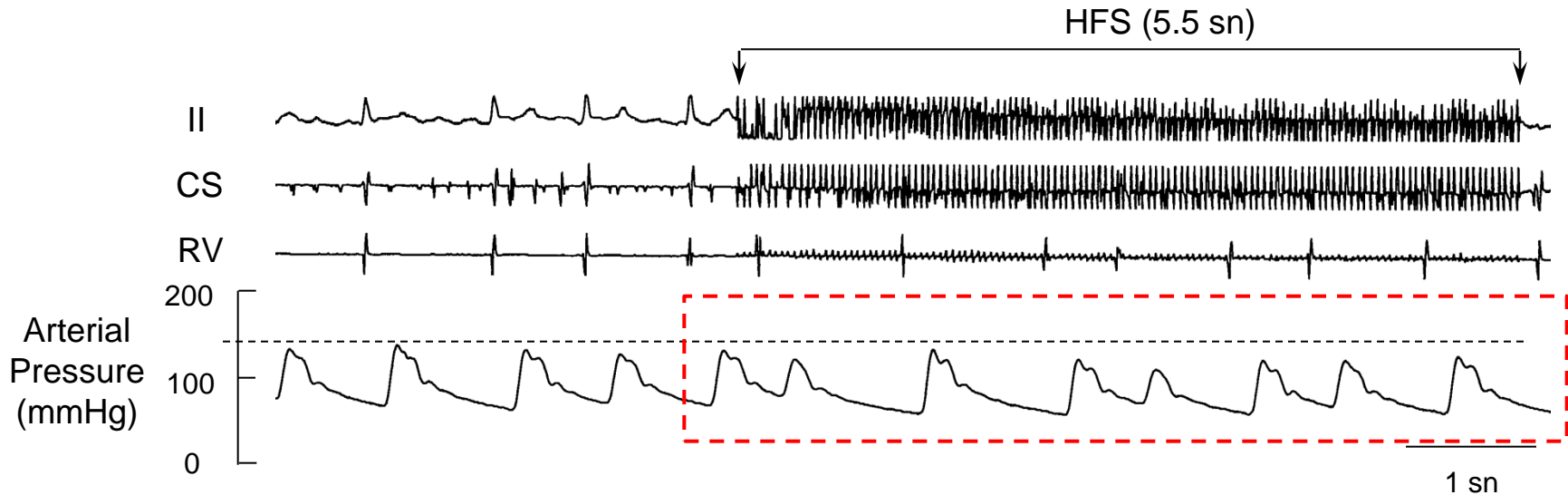
- 3-5 saniye {
- Frekans: 20 Hz
  - Output: 15 V
  - PW: 10 msn



- Ortalama R-R aralığında  $\geq 50\%$  uzama
- Sistolik kan basıncında  $\geq 20$  mmHg düşme



## Ablasyon Öncesi

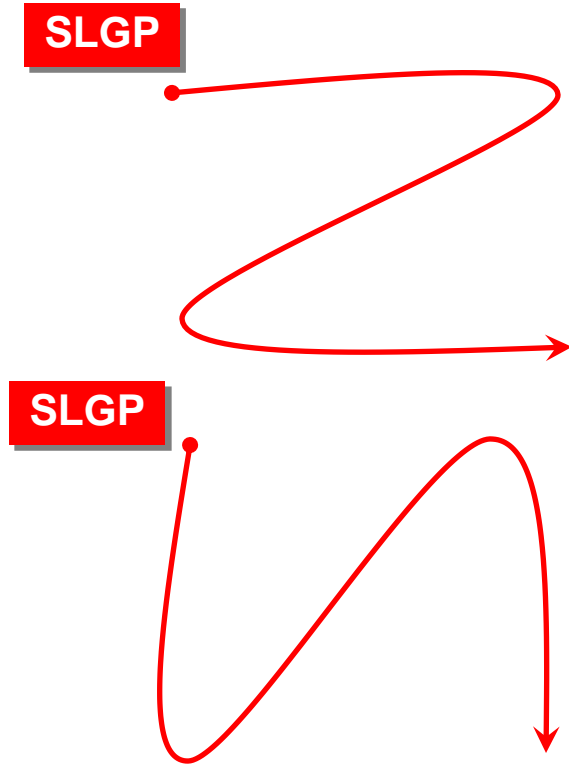


## Ablasyon Sonrası

- **25-35 W**
- **40-60 saniye**
- **Cool-tipped Kateter**

↓  
**ÖZAFAGUS probu!**

- **15-20 W**
- **≤30 saniye**
- **Cool-tipped Kateter**



# **GP Ablasyonu**

**1- Yüksek Frekanslı Stimülasyon: Vagal Cevabın Ortadan Kalkması**

**2- Anatomik Ablasyon: Lokal Atriyal Elektrogramların Kaybı**

# PVI + GP – PVI – GP

## Paroksismal AF

---

### 1. 242 PAF hastası:

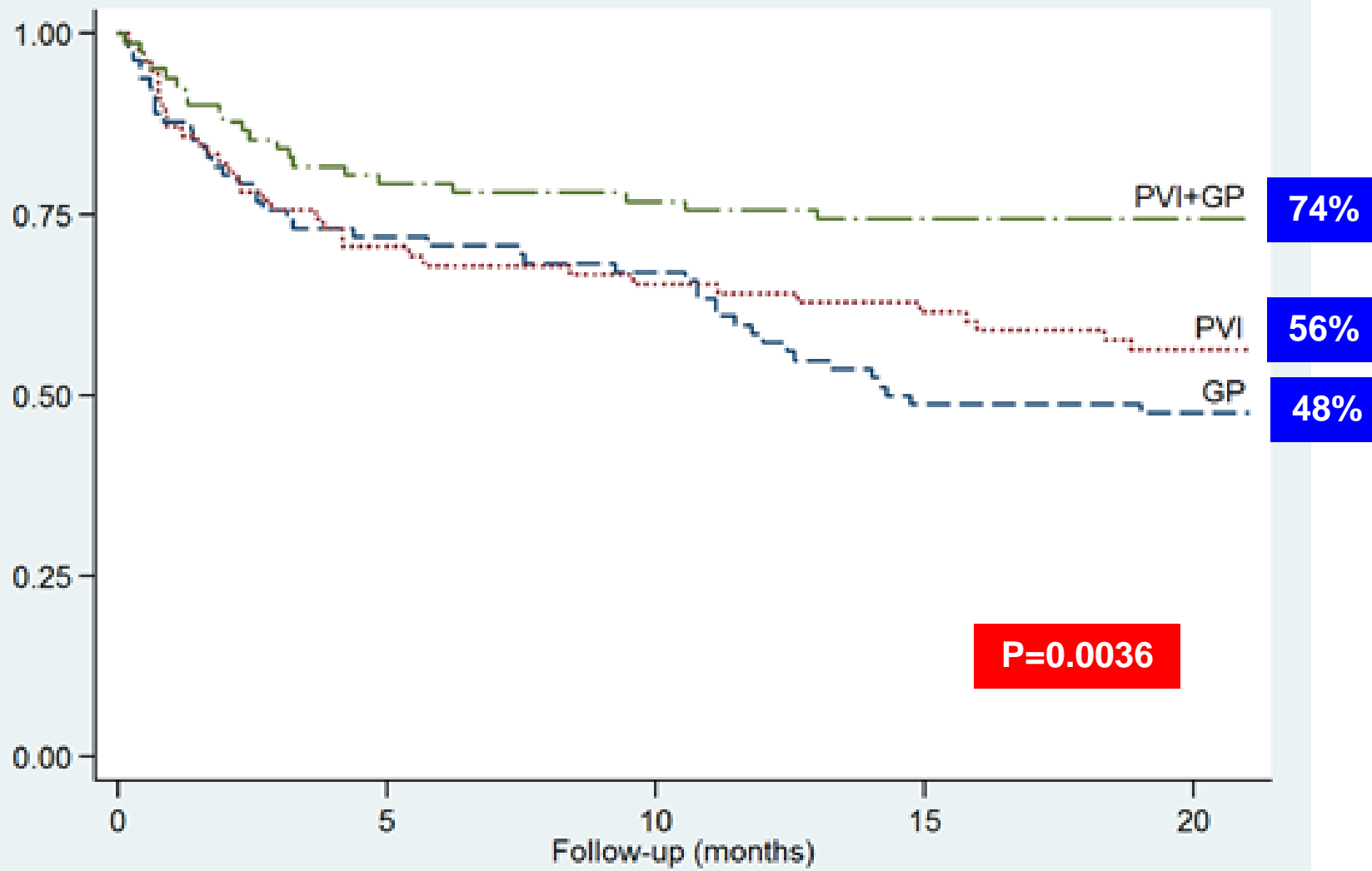
- PVI + Anatomik GP Ablasyonu (n=82)
- PVI (n=78)
- Anatomik GP Ablasyonu (n=82)

### 2. Takip — 2 yıl:

- Aylık Holter monitorizasyonu
- 112 hastada ILR (+)



Proportion of AF/AT free Patients



Number at risk

GP	82	59	55	40	39
PVI	78	55	51	48	44
PVI+GP	82	65	63	61	60

# PVI + GP Ablasyonu -- PVI + Linear Ablasyon

## Persistent / Uzun Süreli Persistent AF

---

### 1. 264 hasta:

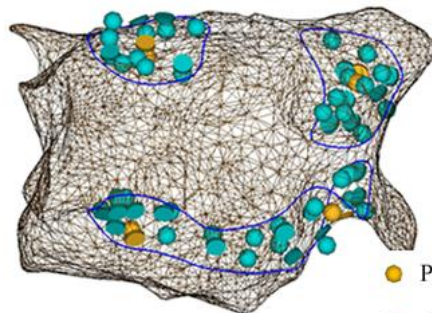
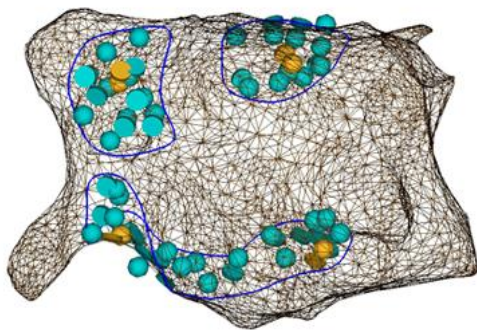
- PVI + GP Ablasyonu: N=132
- PVI + Tavan/Mitral İstmus Hattı: N=132

### 2. Takip – 3 yıl:

- Tüm hastalarda ILR (+)
- AARx olmadan AF <0.5% (3.6 saat/1 ay) rekkürens olarak kabul edilmemiş.

Pokushalov E, ve ark. Ganglionated Plexi Ablation vs Linear Ablation in Patients Undergoing Pulmonary Vein Isolation for Persistent/Longstanding Persistent Atrial Fibrillation: A Randomized Comparison. Heart Rhythm 2013 Apr 19.

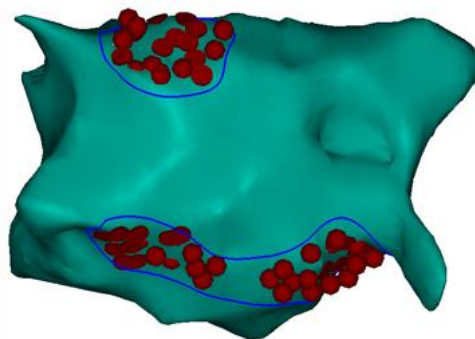
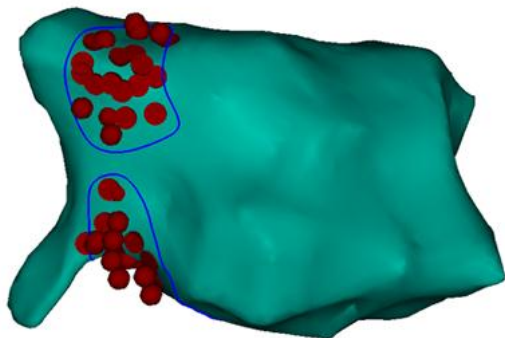
A



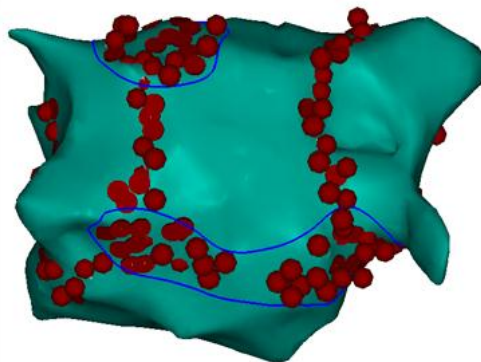
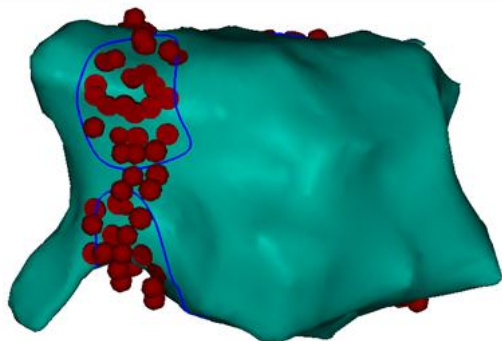
● Positive vagal response

● CFAE

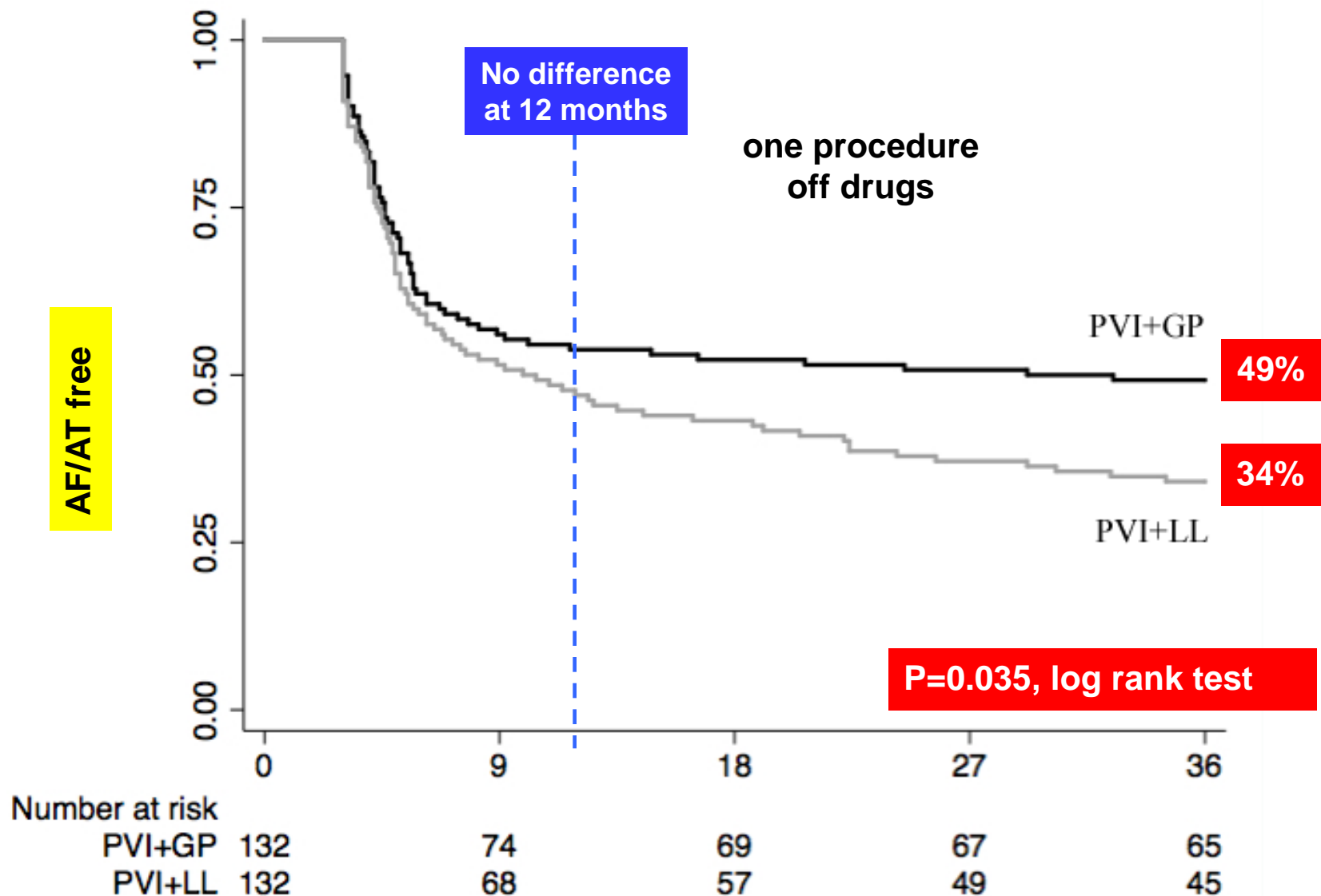
B



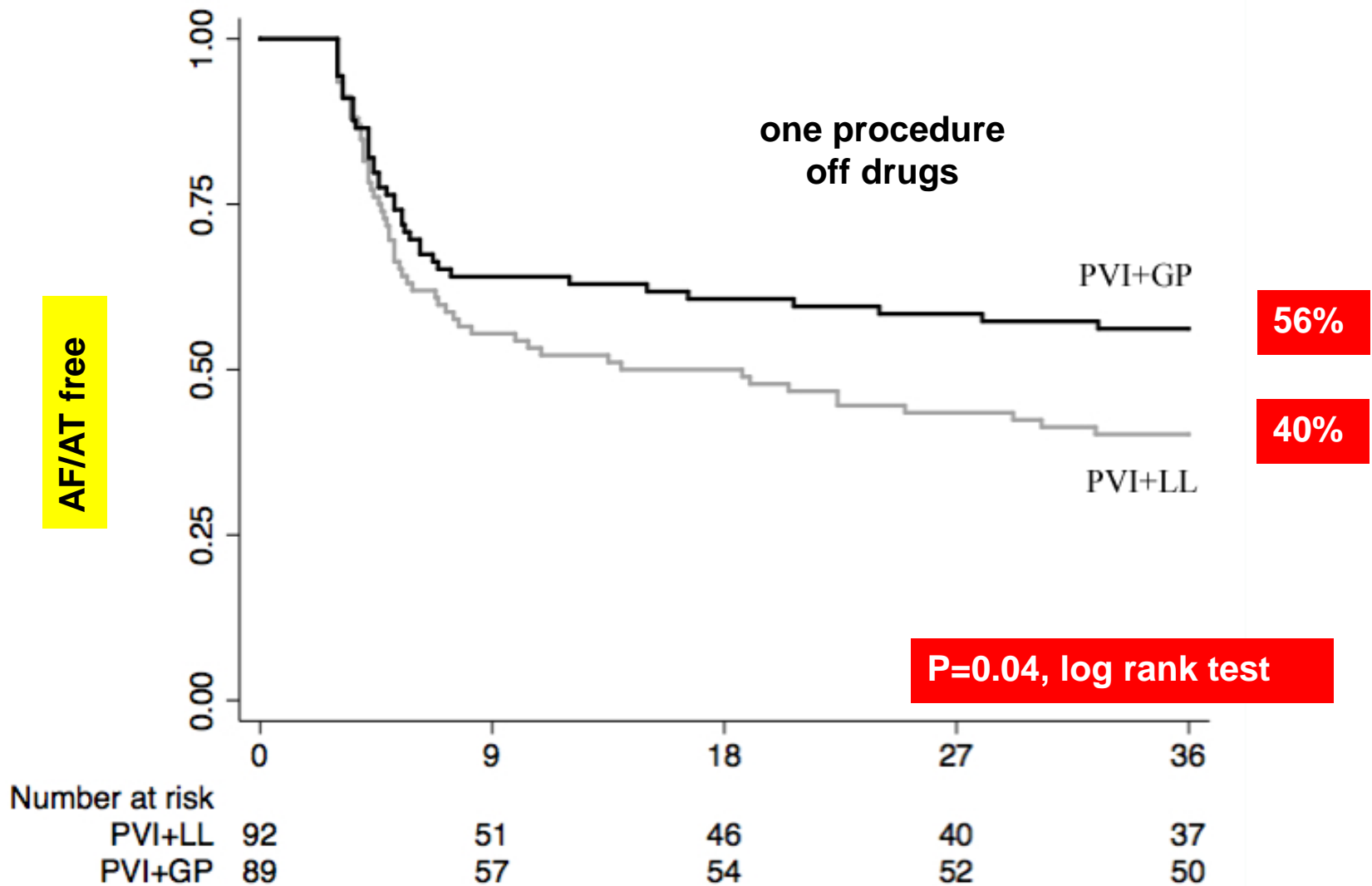
C



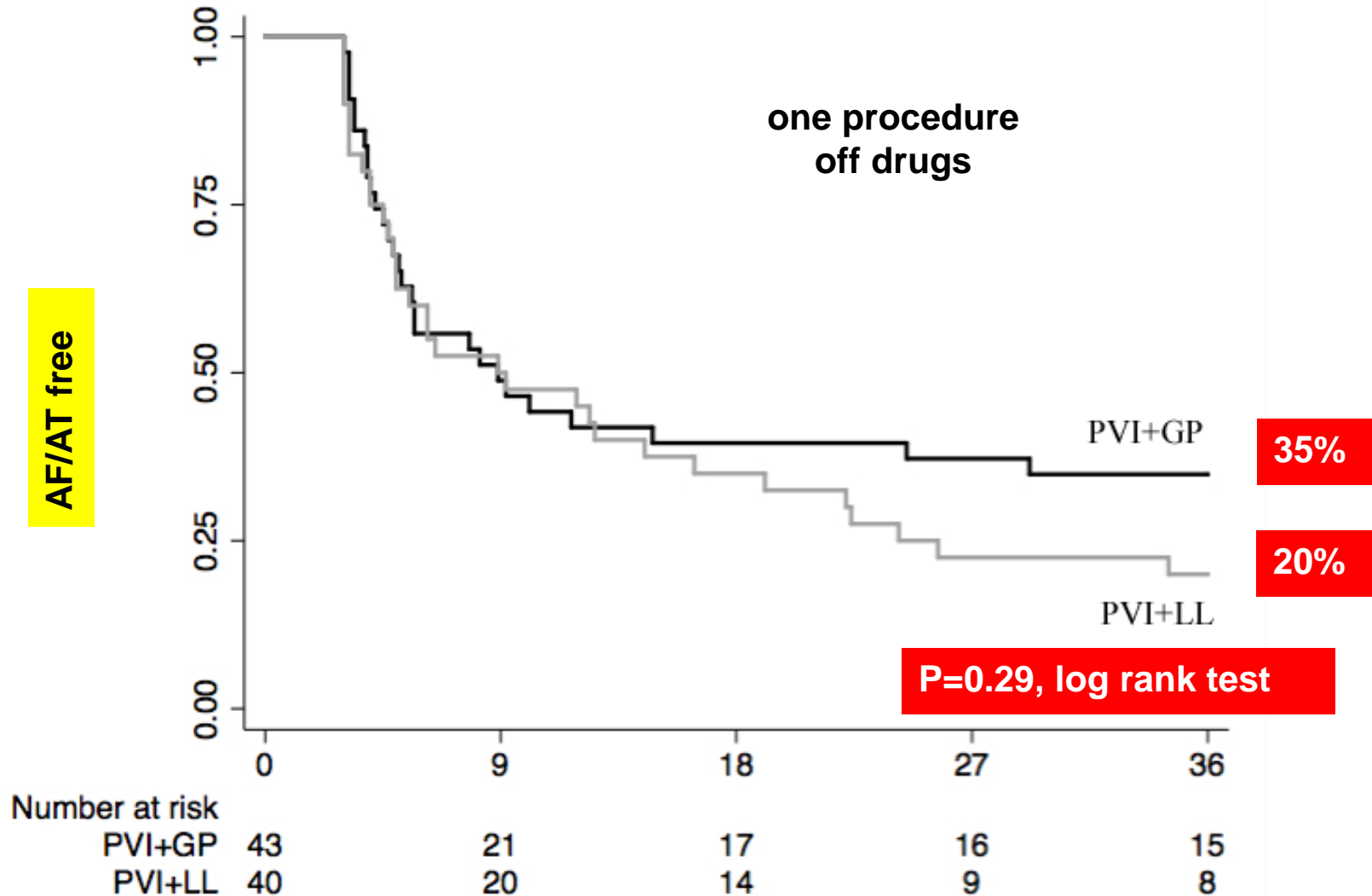
# AF/AT Free: Persistent + Longstanding Persistent AF

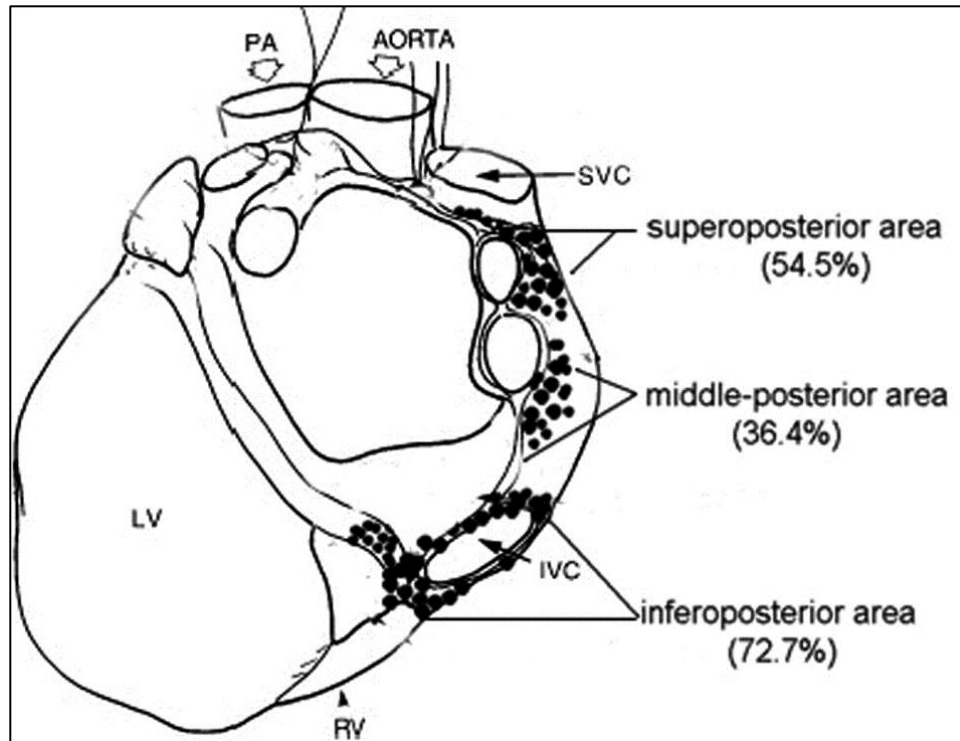


# AF/AT Free: Persistent AF



# AF/AT Free: Longstanding Persistent AF





Calo L, et al. Catheter ablation of right atrial ganglionated plexi in patients with **vagal paroxysmal atrial fibrillation**.  
Circ Arrhythm Electrophysiol 2012;5:22-31.