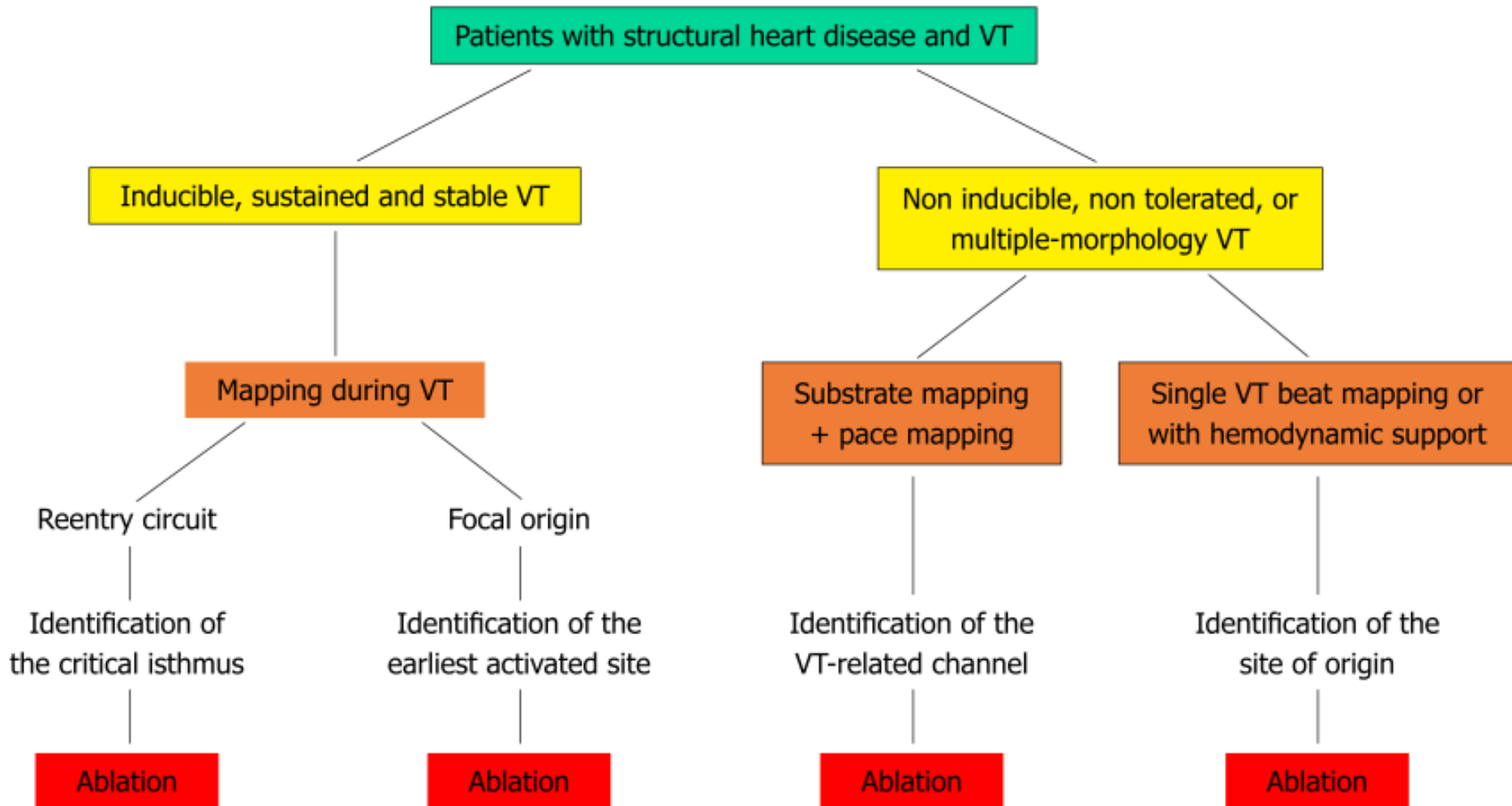


# Ventriküler Taşikardi Substrat Ablasyonu

Doç. Dr. Duhan Fatih Bayrak  
Acıbadem Üniversitesi, İstanbul

# VT - Ablasyon stratejileri



# Ne zaman kullanılmalı?

- Yapısal kalp hastalığı varlığında hemen her zaman
- VT indüklenemiyorsa
- Nonklinik VT indükleniyorsa
- Hemodinamik olarak tolere edilemeyen VT
- Klinik hemodinamiyi bozmayan VT (VT süresini kısaltmak amaçlı)

# Kullanılan Teknik

- 3 boyutlu elektroanatomik haritalama sistemleri yardımı ile sinüs ritminde bipolar ve unipolar voltaj haritaları (nadiren pacing altında)
  - CARTO
  - EnSite

# Substrat Haritasındaki Bilgiler

- Skar alanı (ineksitabilite olan dense skar)
- Skar sınır alanı (border zone)
- Skar içi iletebilen kanalların tespiti
- Geç potansiyellerin tespiti
- Taşikardi çıkış ve giriş noktalarının sinüs ritminde pace mapping ile tespiti

# Endokardiyal Bipolar Voltaj Haritası

- Standart ayarlar (yeterli kontakt gücü)
  - 0.5 mV altı skar
  - 0.5-1.5 mV arası geçiş zonu
  - 1.5 mV üstü sağlıklı doku

# Epikardiyal Bipolar Voltaj Haritası

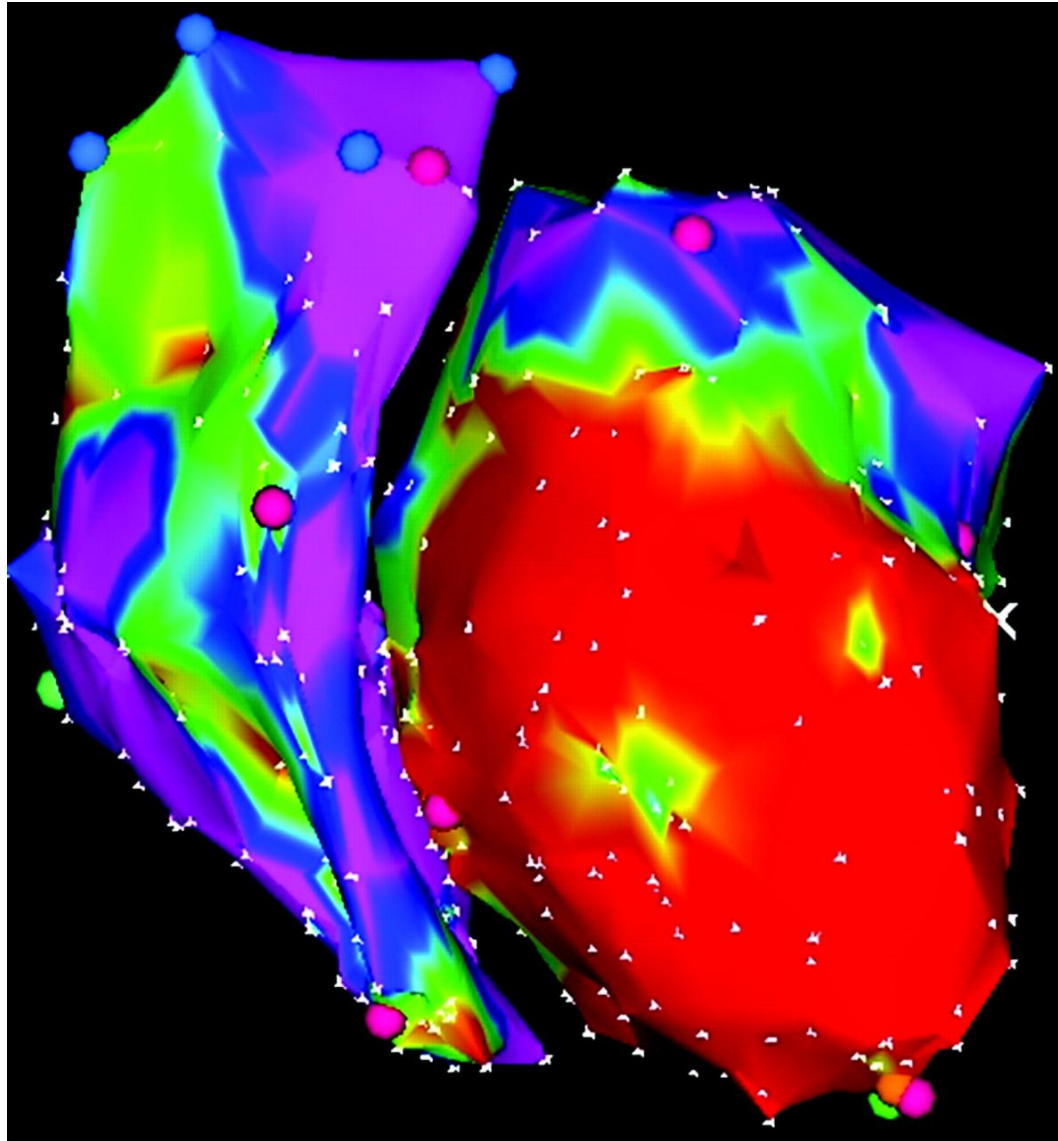
- Standart ayarlar
  - 0.5 mV altı skar
  - 0.5-1.0 mV arası geçiş zonu
  - 1.0 mV üstü sağlıklı doku (epikardiyal yağ dokusu)

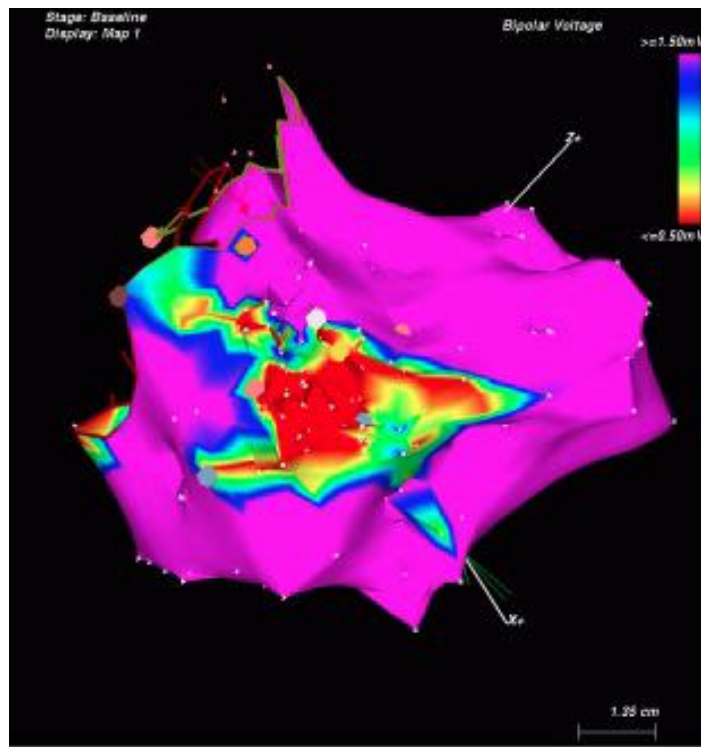
# Endokardiyal Unipolar Voltaj Haritası

- Standart ayarlar
  - 0.5 mV altı skar
  - 0.5-5.5 mV (ARVD), 0.5-8.3 mV arası geçiş zonu (DKMP)
  - 5.5 mV (ARVD), 8.3 mV (DKMP) üstü sağlıklı doku



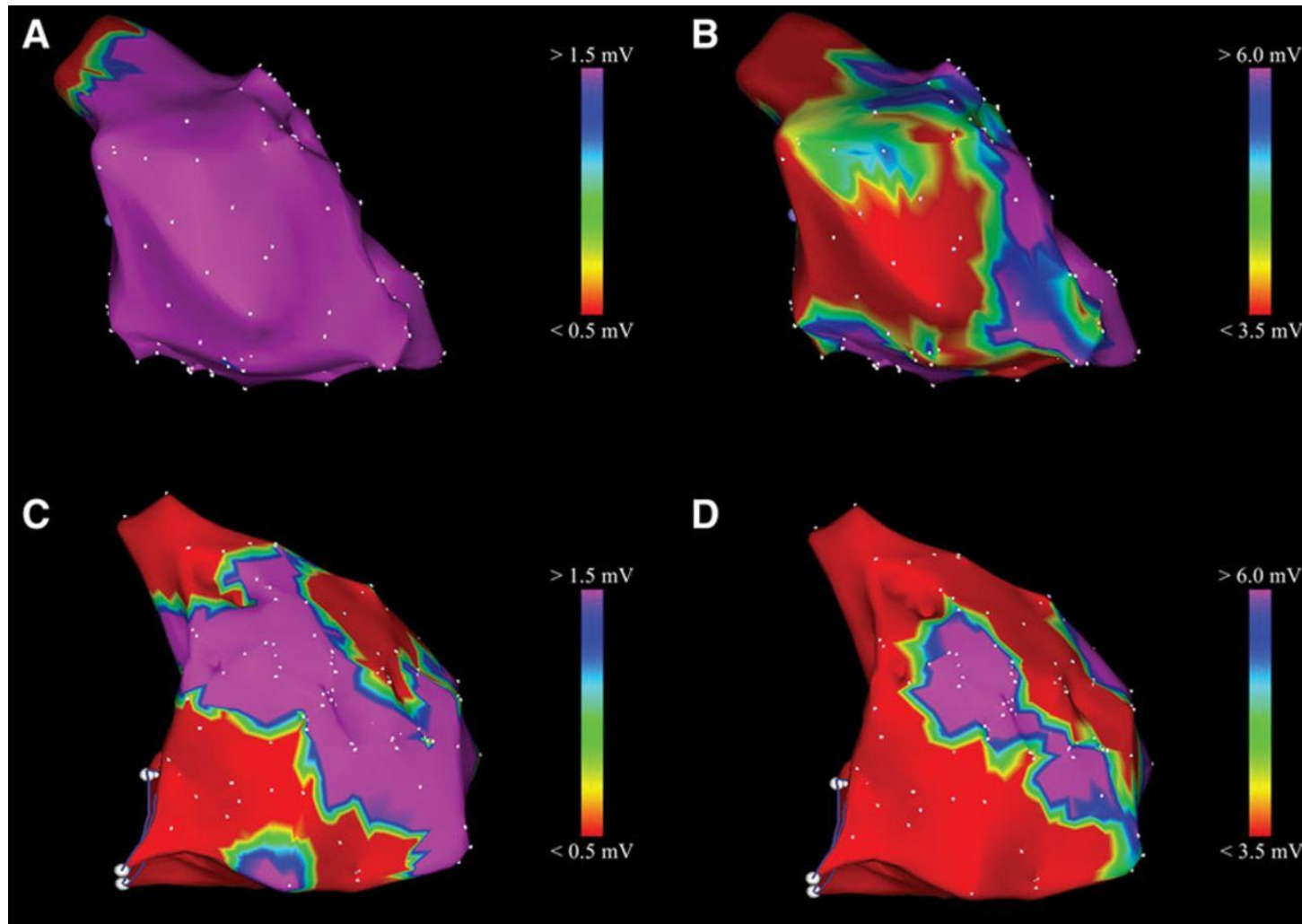
# Endo bipolar





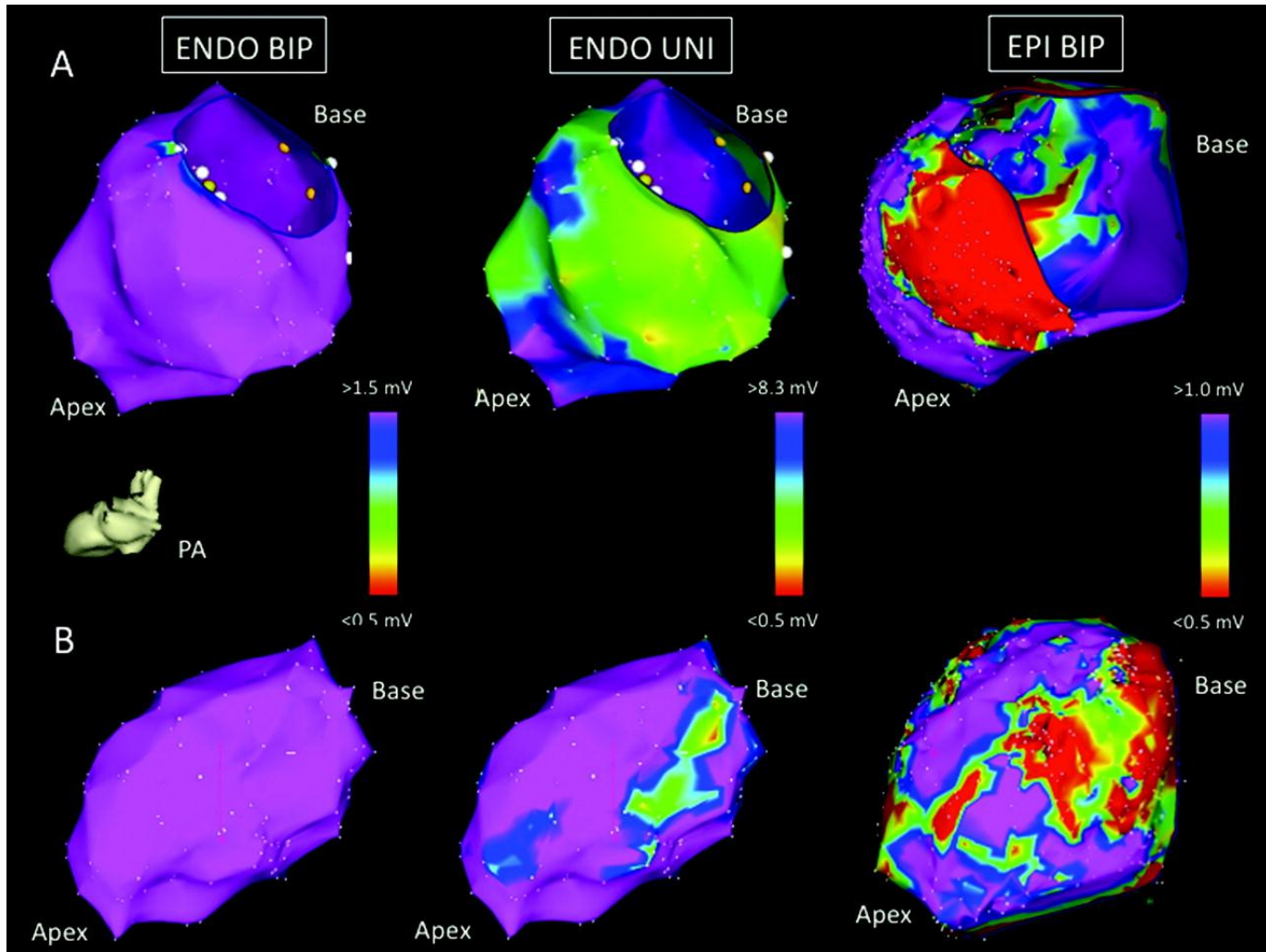
Endo Unipolar

Representative bipolar and unipolar right ventricular (RV) endocardial voltage mapping (EVM) from 2 arrhythmogenic right ventricular cardiomyopathy/dysplasia patients.



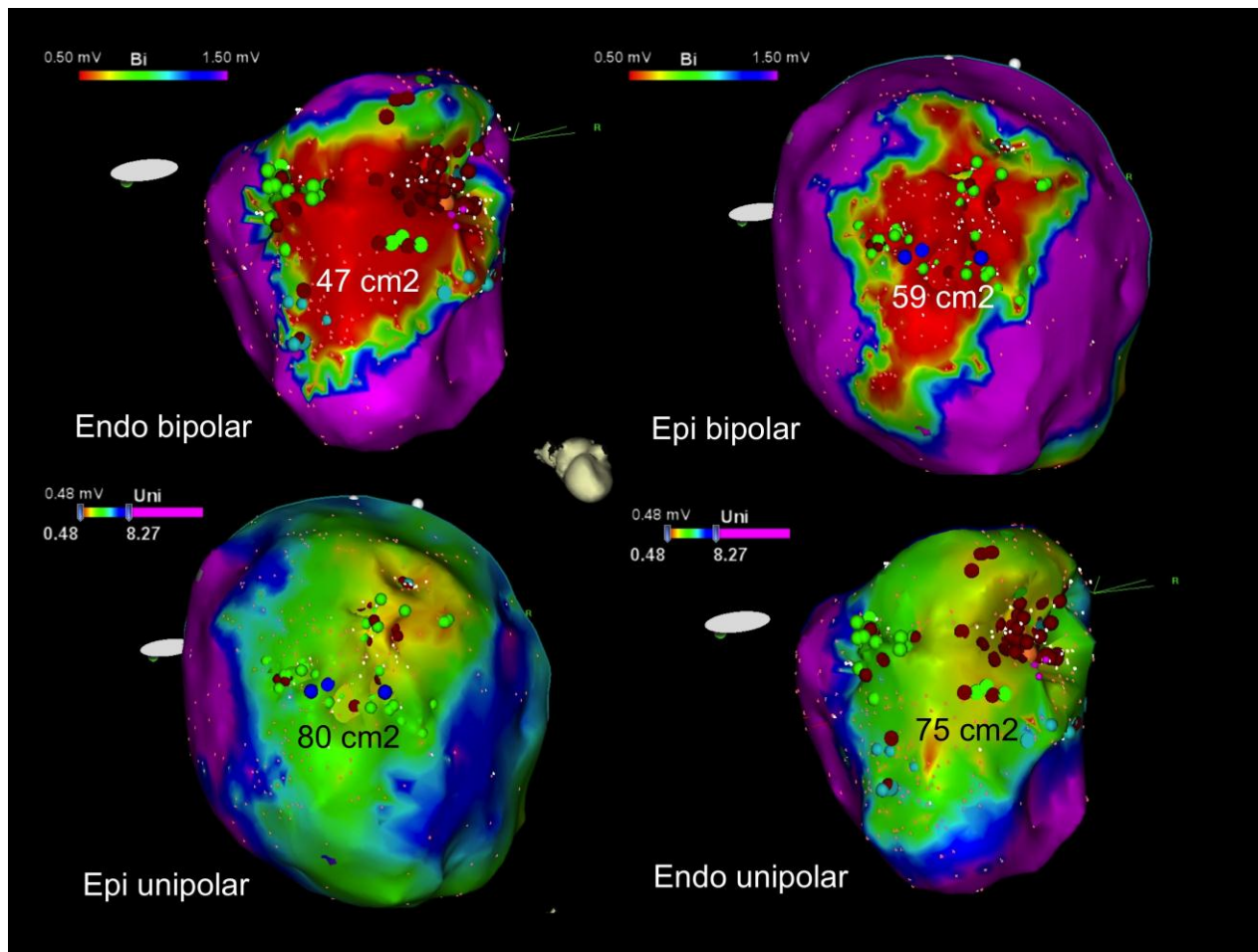
Migliore F et al. *Circ Arrhythm Electrophysiol.* 2013;6:167-176

Images taken from 2 EPI+ patients in the posterior-anterior (PA) projection: patient 5 (A) and patient 7 (B).

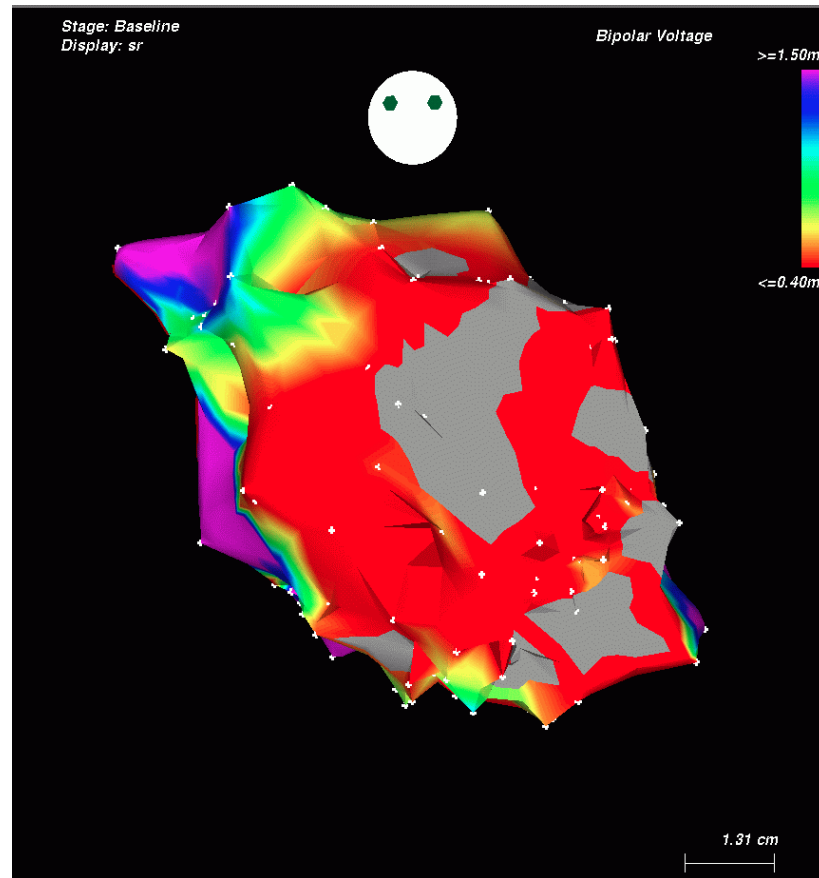


Hutchinson M et al. *Circ Arrhythm Electrophysiol*  
2011;4:49-55

Epi bipolar



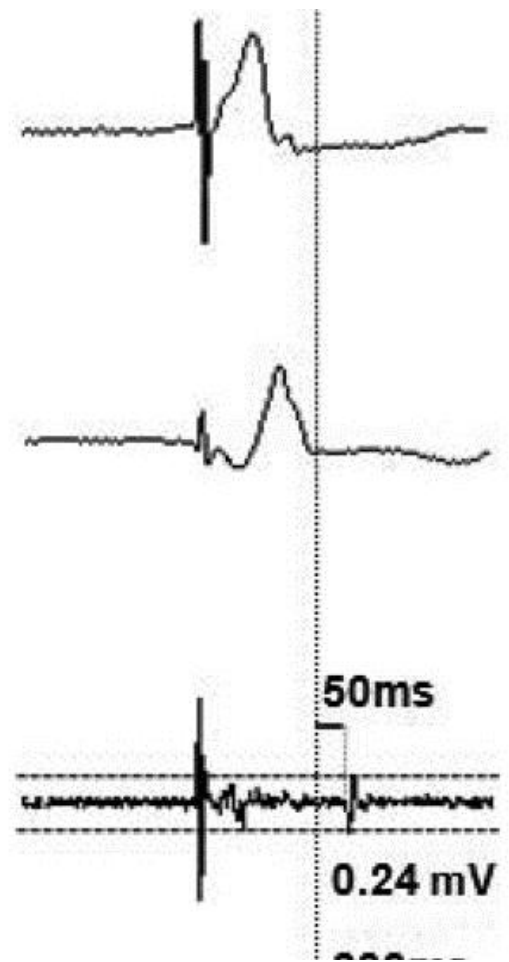
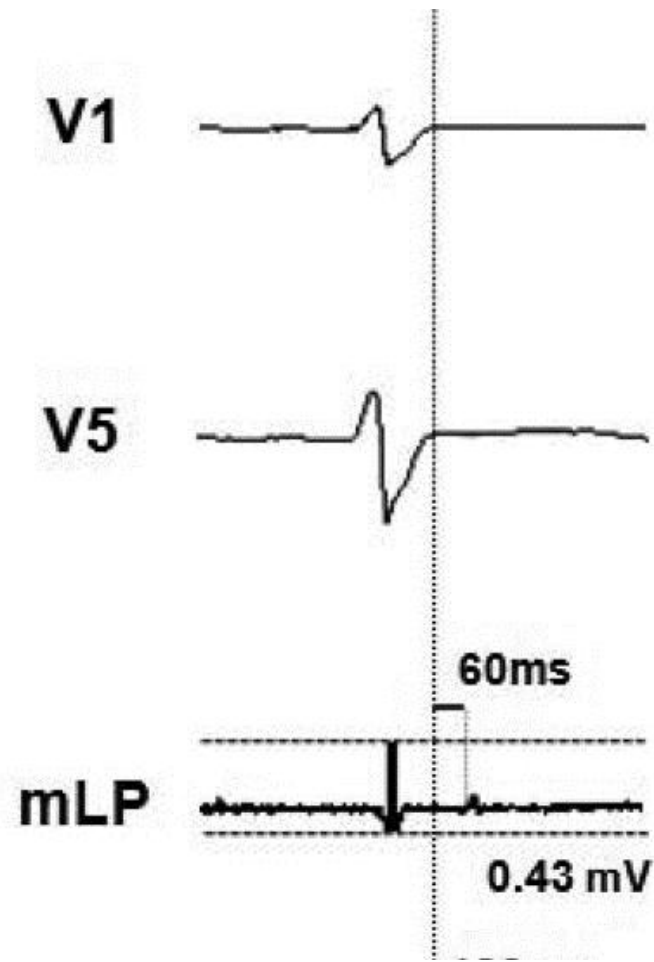
# İneksitable Skar Belirlenmesi

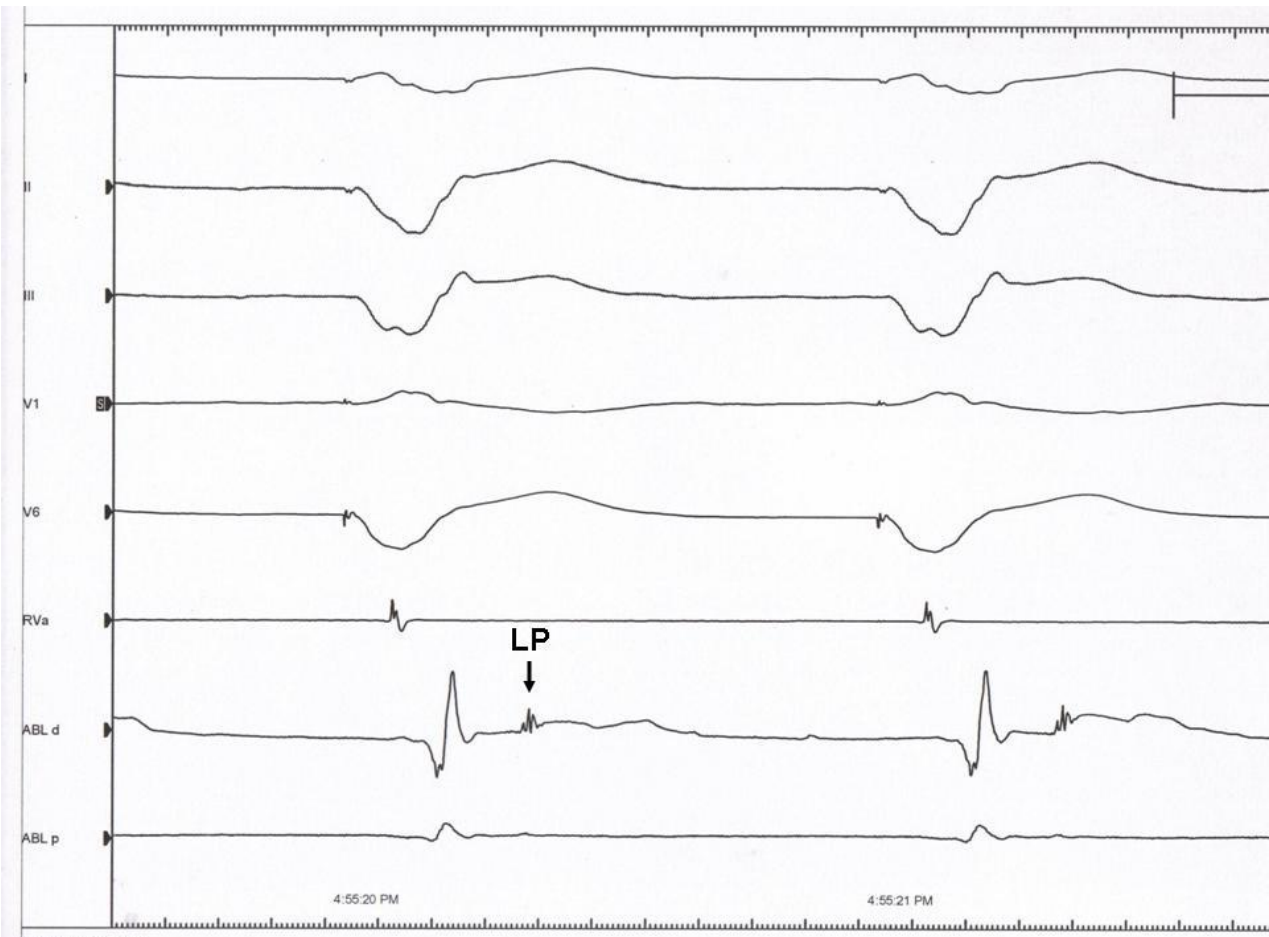


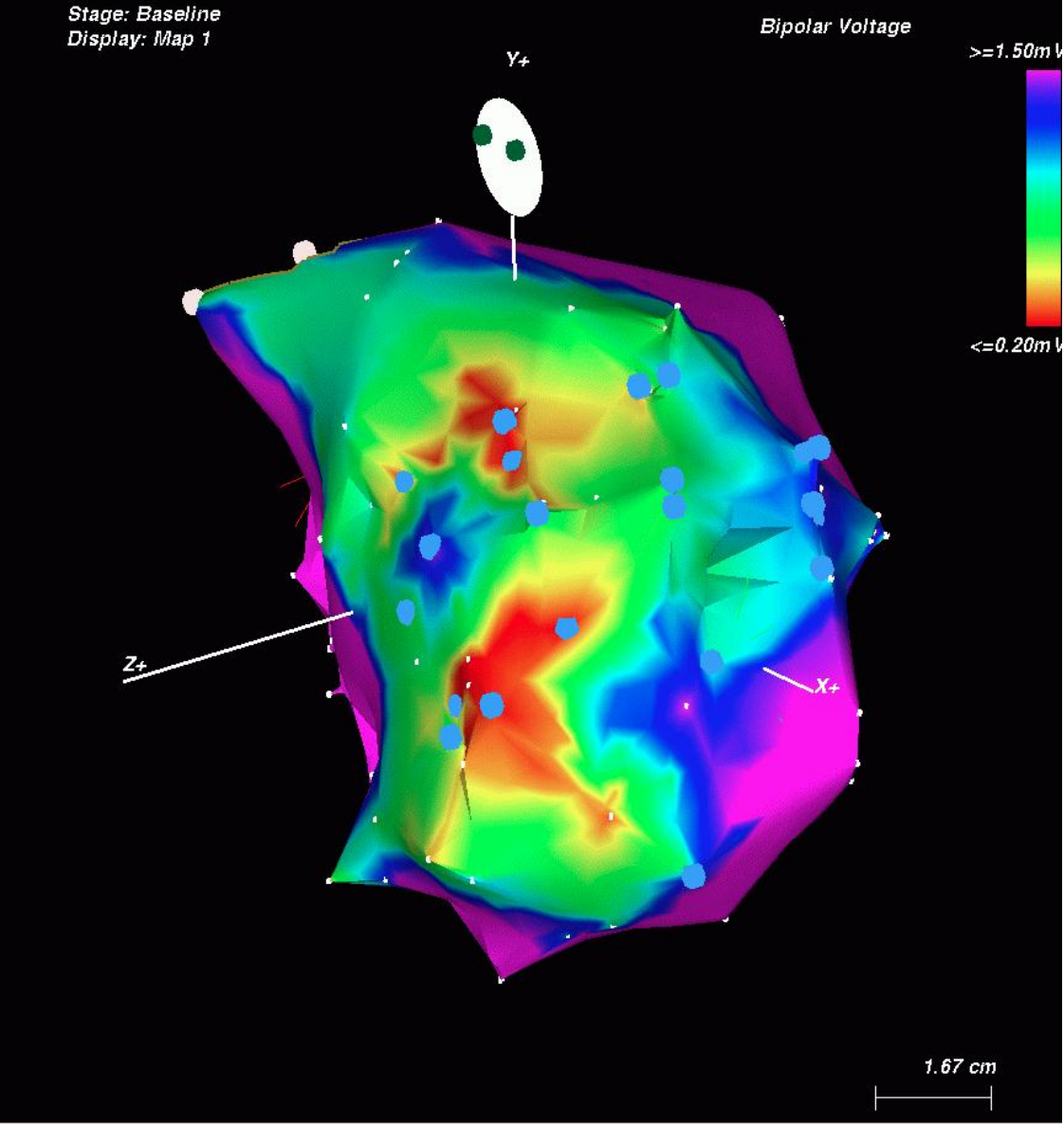


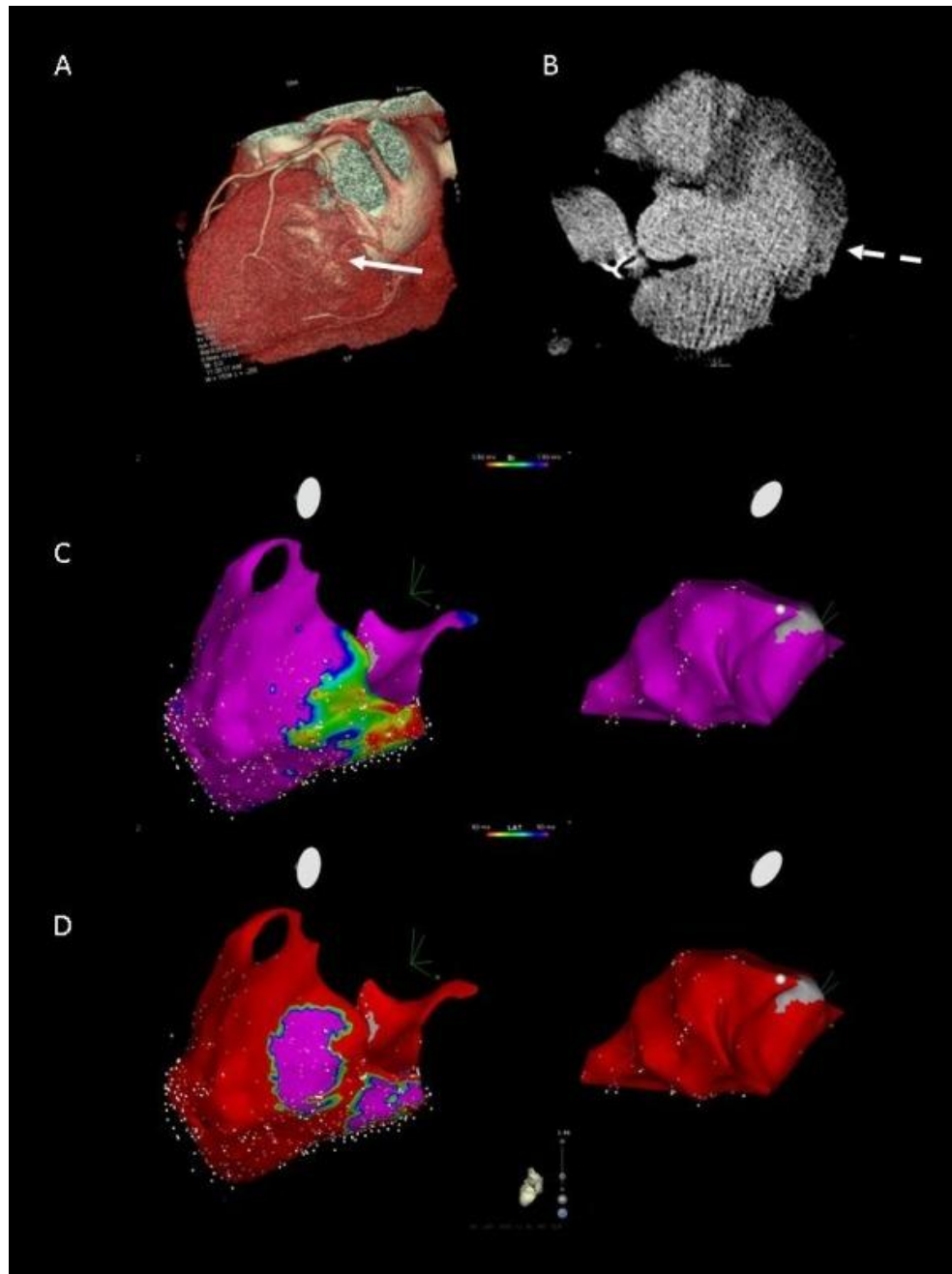
# Geç Potansiyel Haritalaması

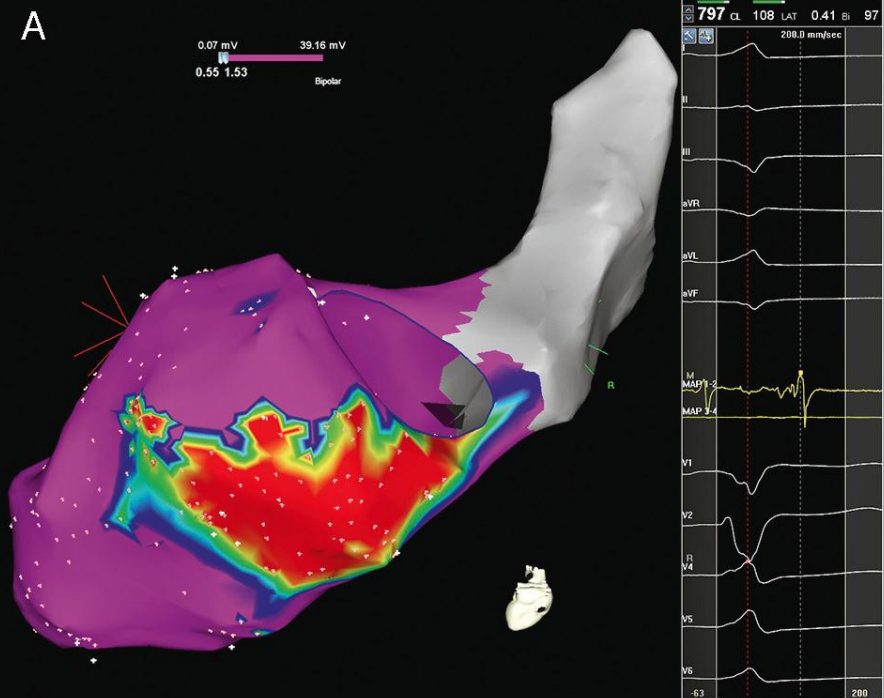
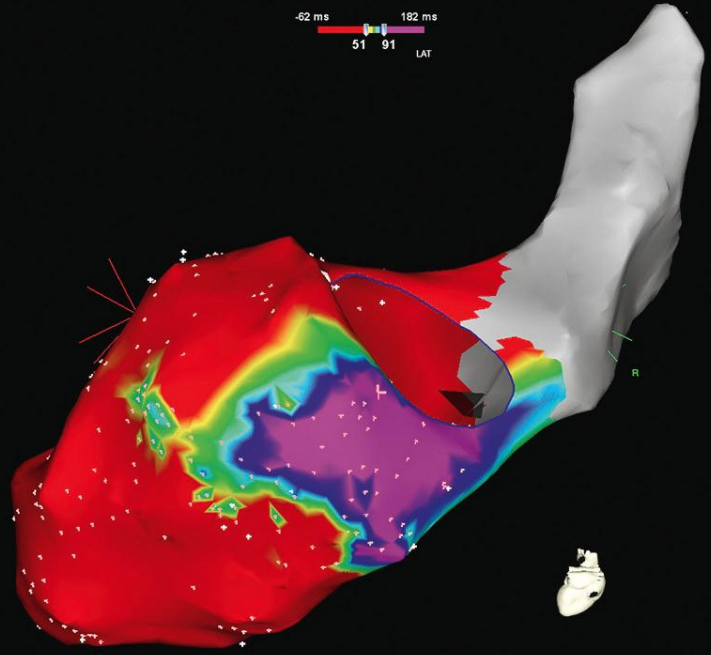
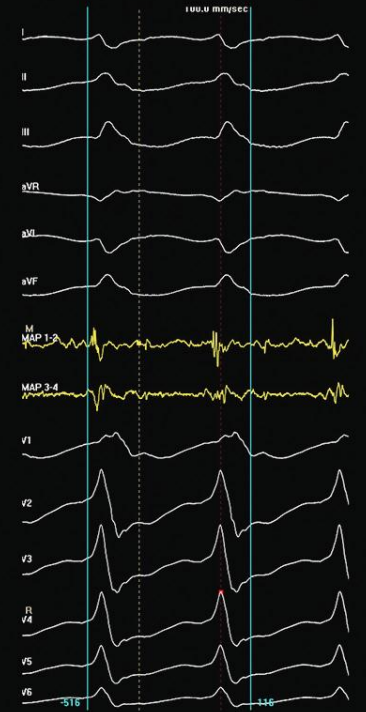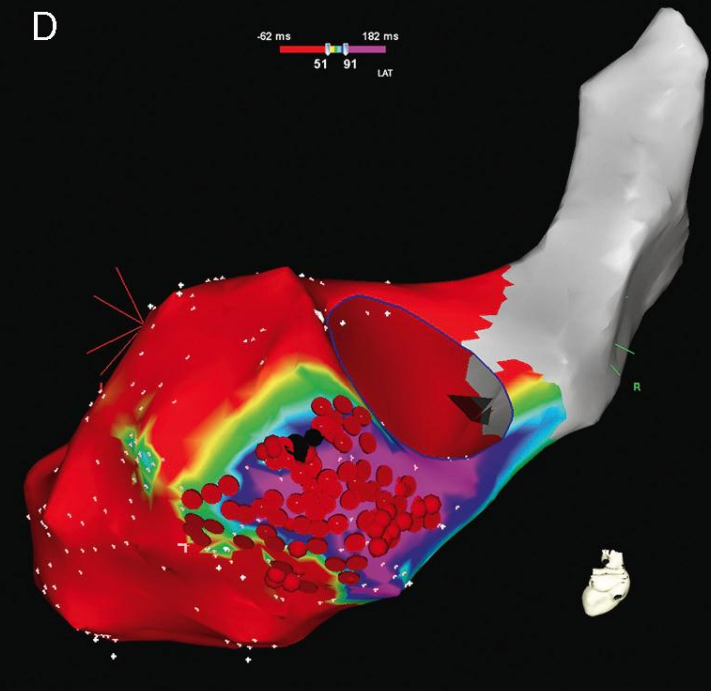
- Voltaj haritalamasına ek olarak LAT haritalaması kullanılarak yapılır







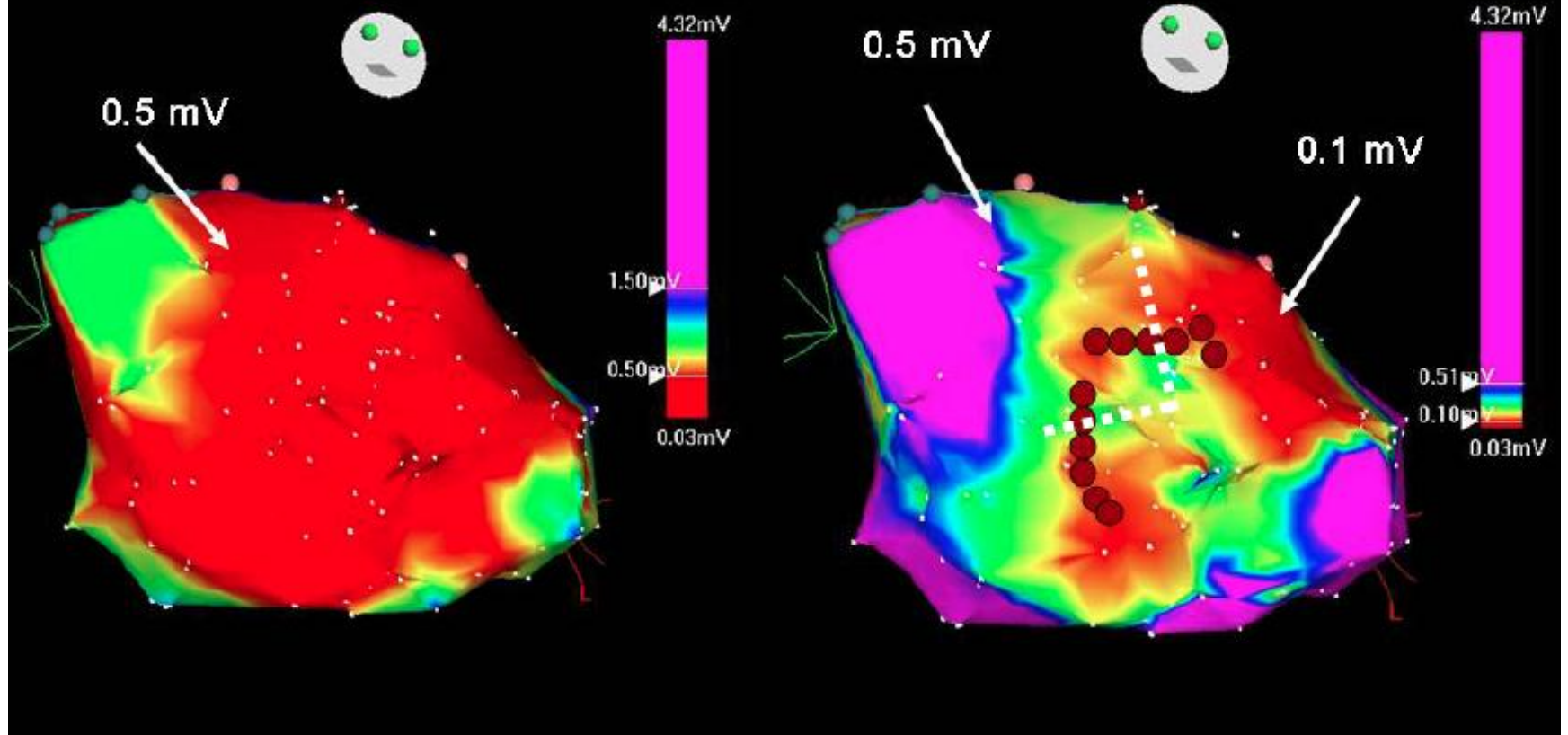


**A****B****C****D**

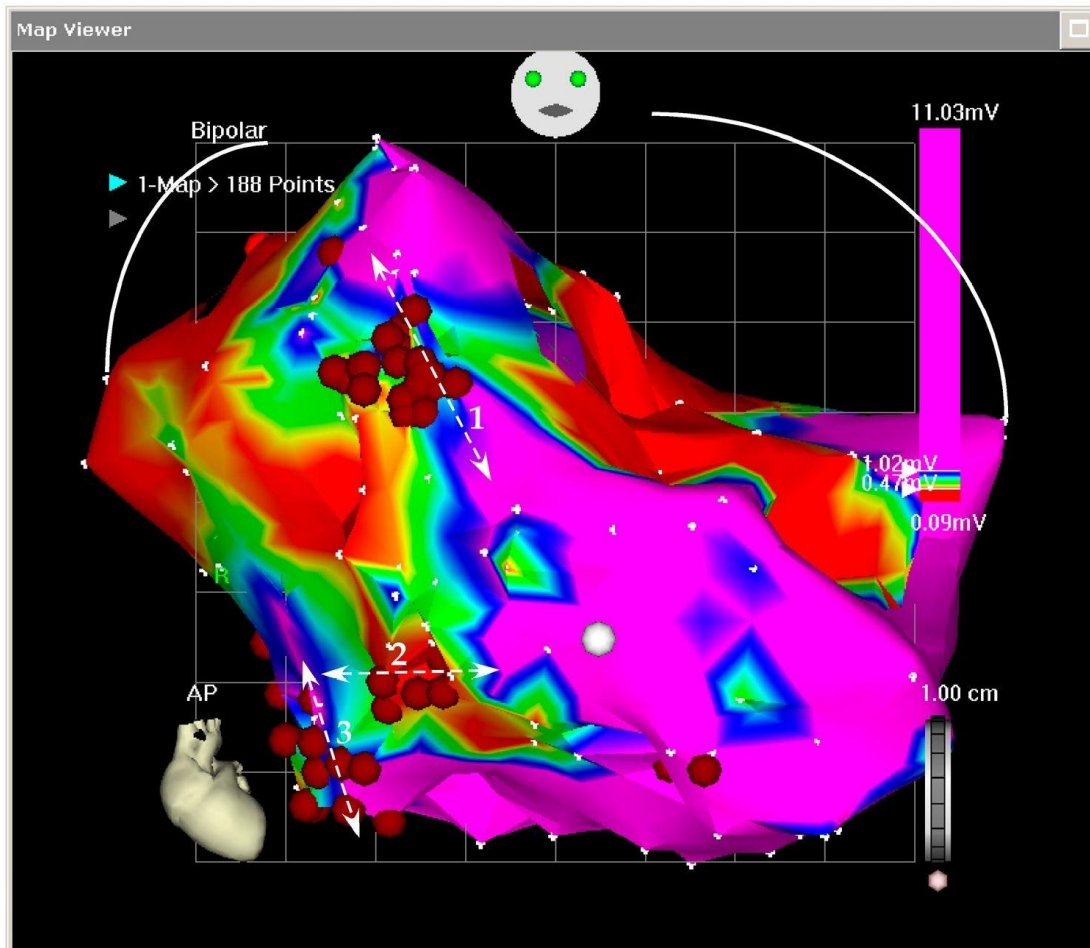
# Skar İçi Kanal Haritası

- Bipolar voltaj kriterleri
  - 0.2-0.5 mV olarak değiştirilir
  - Skar içi nispeten yüksek voltajlı elektriksel olarak iletibilen bölgelerin tespiti

# Voltage Criteria for Scar

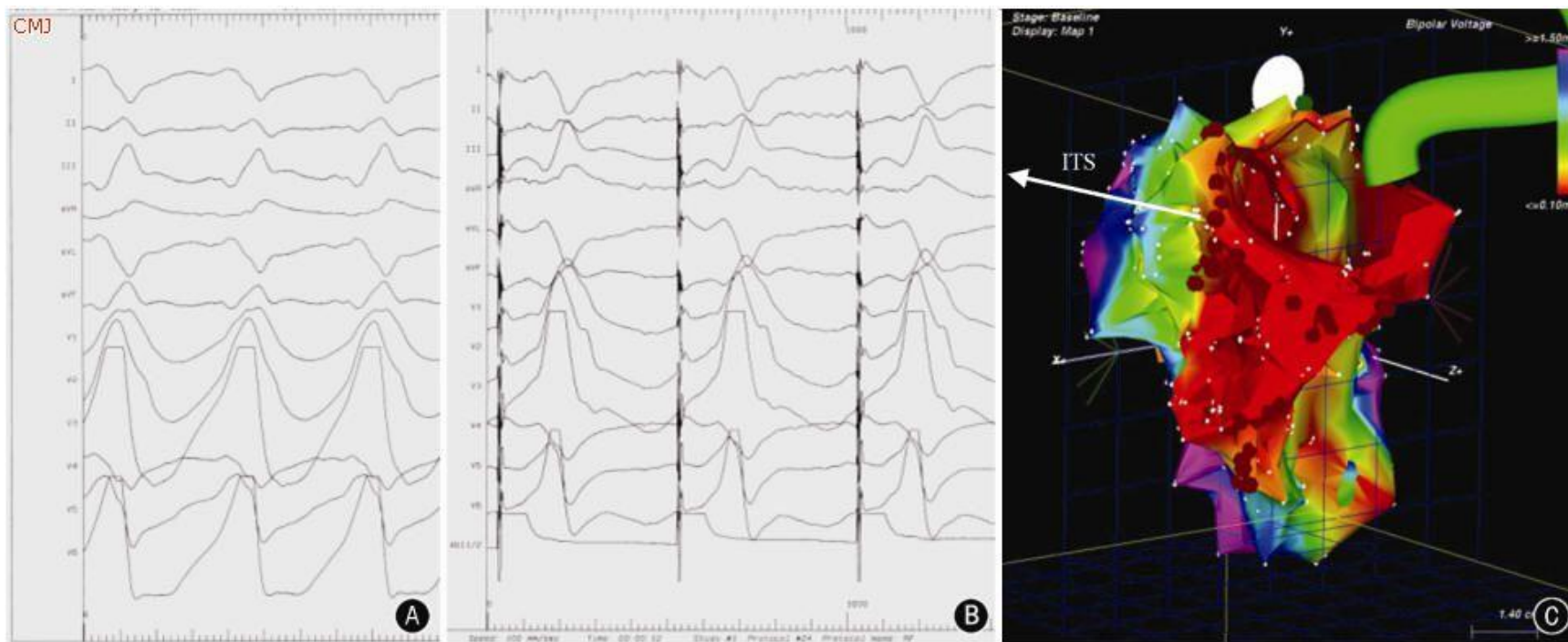




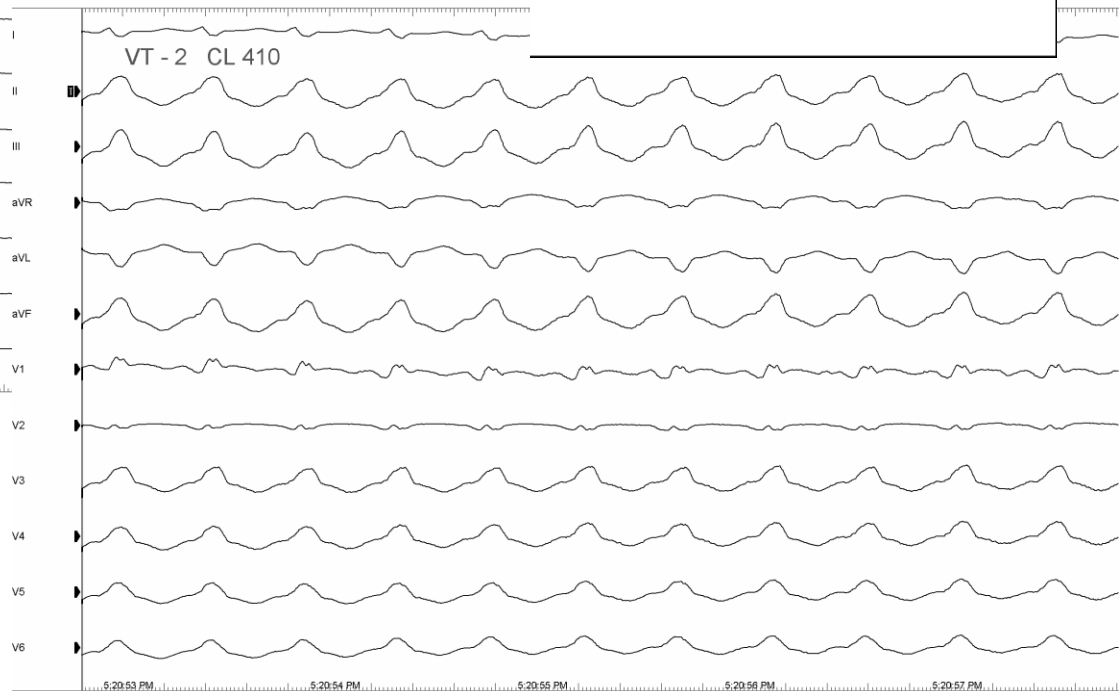
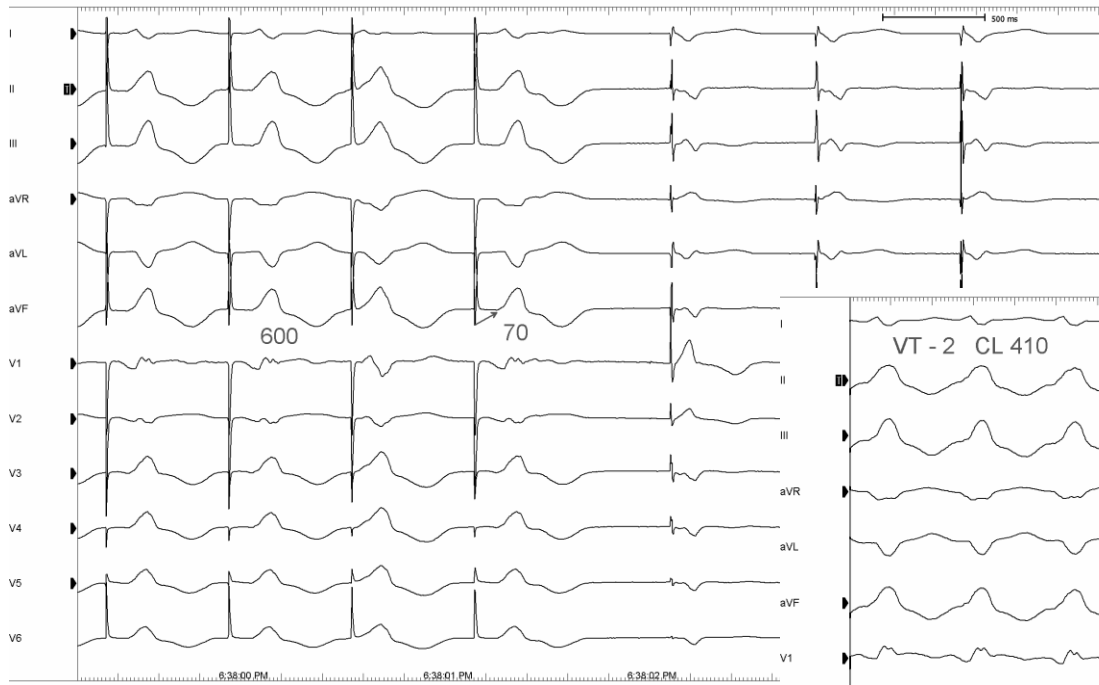
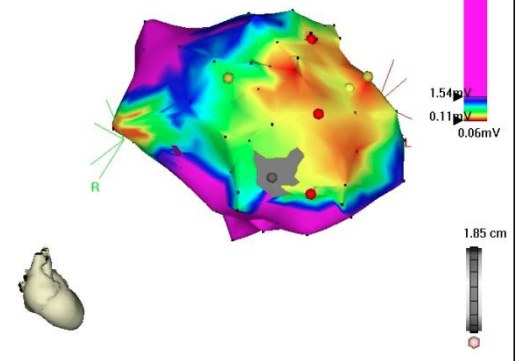


# Pace Mapping

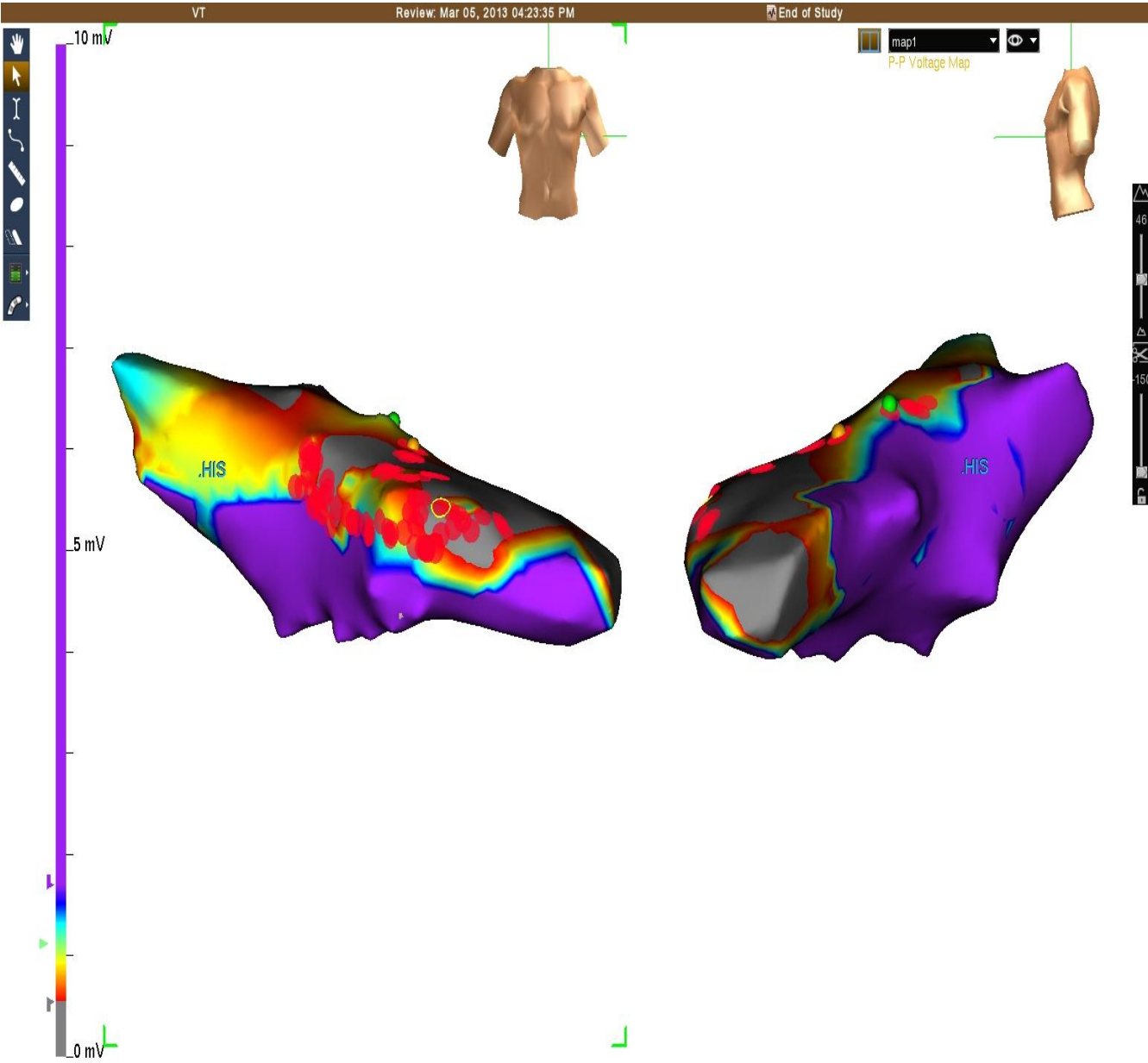
- Substrat haritası tamamlandıktan sonra skar border zone bölgelerinde VT morfolojisine benzer QRS morfolojisi elde edilen bölge VT çıkış bölgesidir.
- Pacing taşikardi ile aynı siklüs uzunluğunda yapılmalıdır.

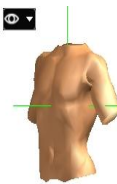
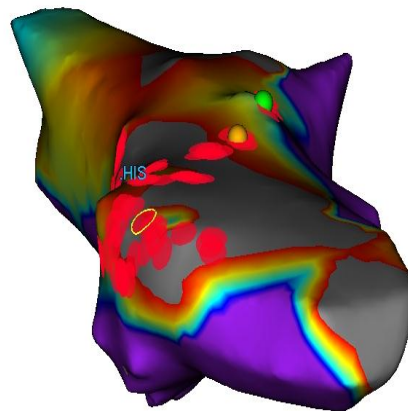
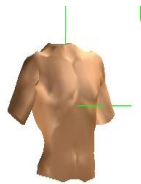
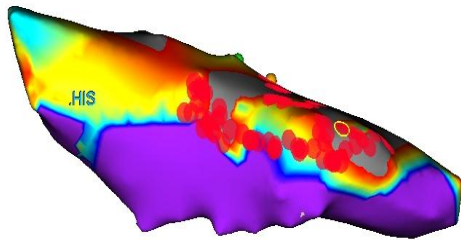
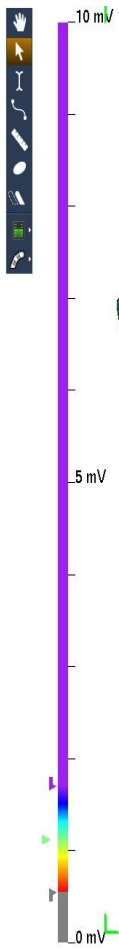


Bipolar  
▶ 2-SR LV endo > 89 Points



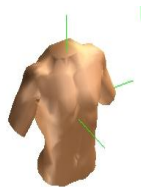
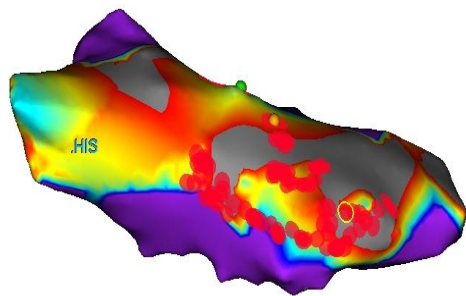
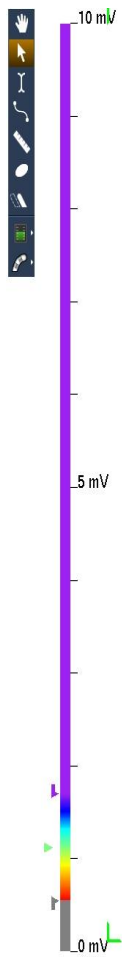
# Substrat Bazlı Ablasyon Stratejileri



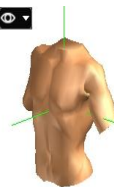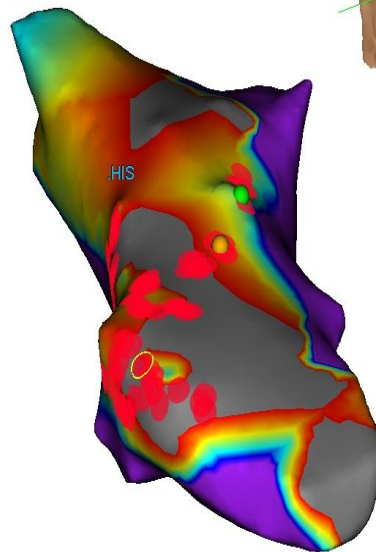


map1  
P-P Voltage Map





map1  
P-P Voltage Map

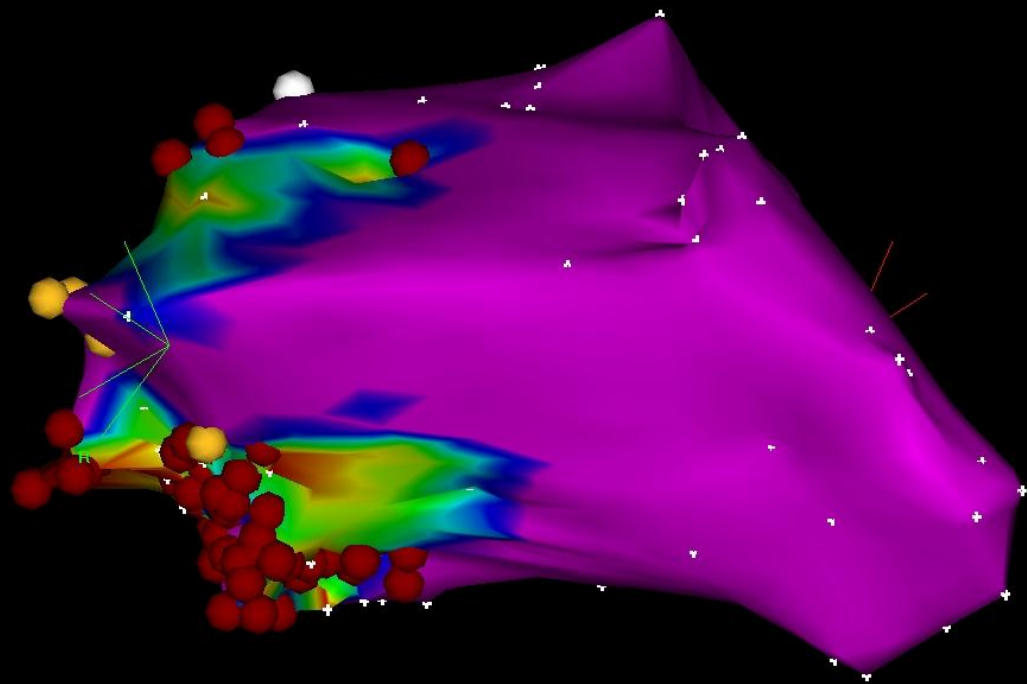




1-Map (184, 0)



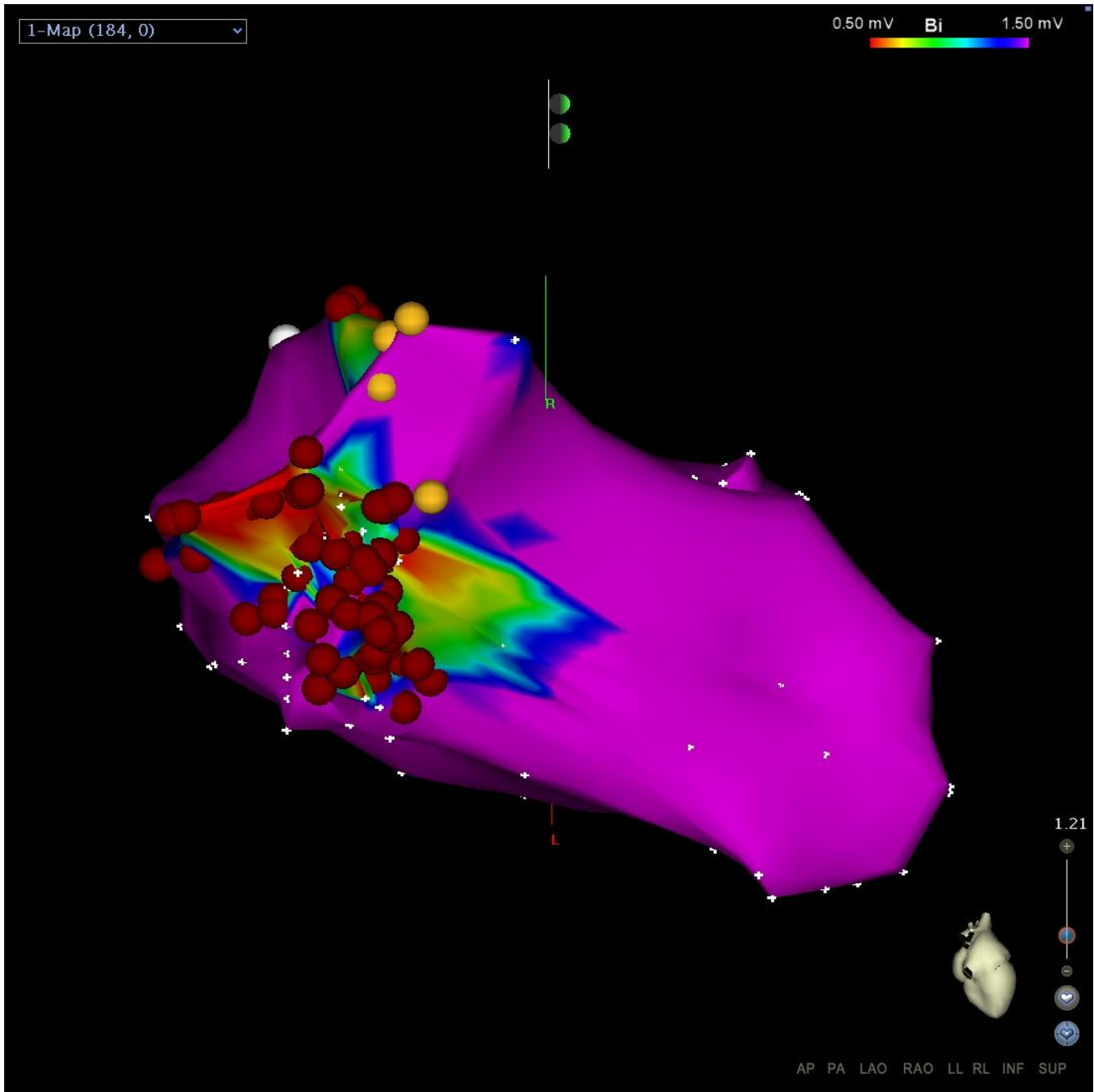
0.50 mV **Bi** 1.50 mV



1.21

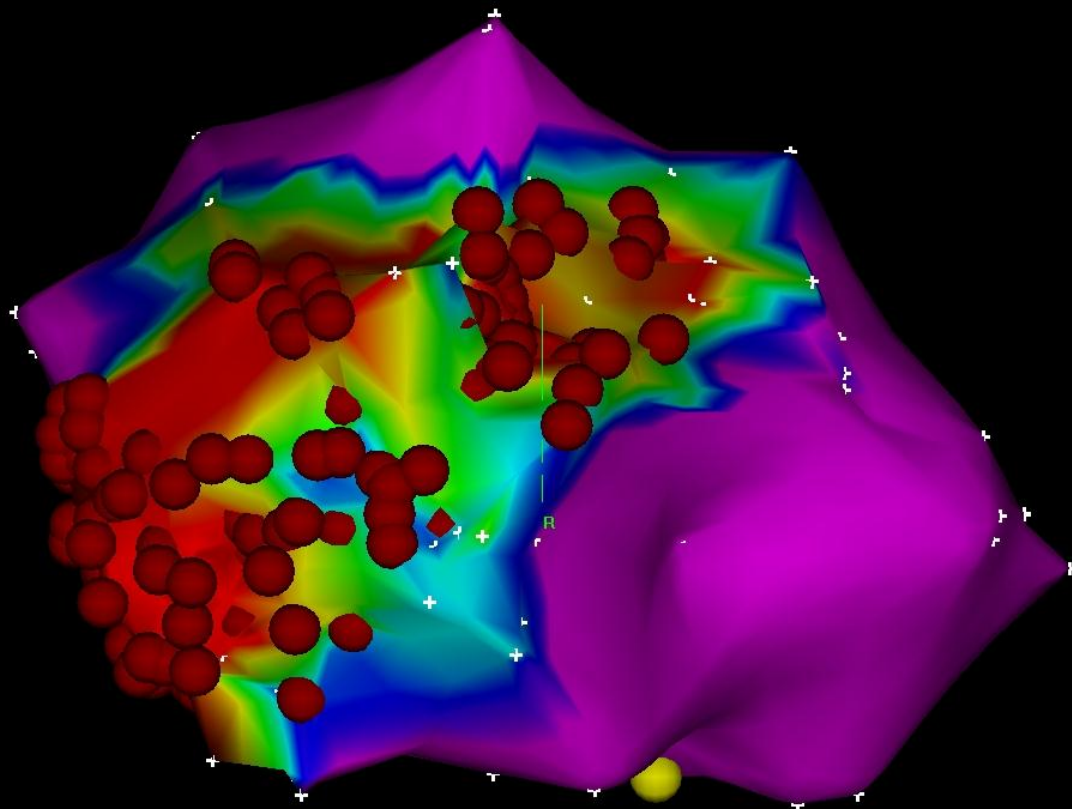


AP PA LAO RAO LL RL INF SUP

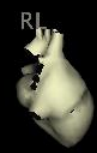


1-Map (216, 0)

0.50 mV **Bi** 1.50 mV



1.00

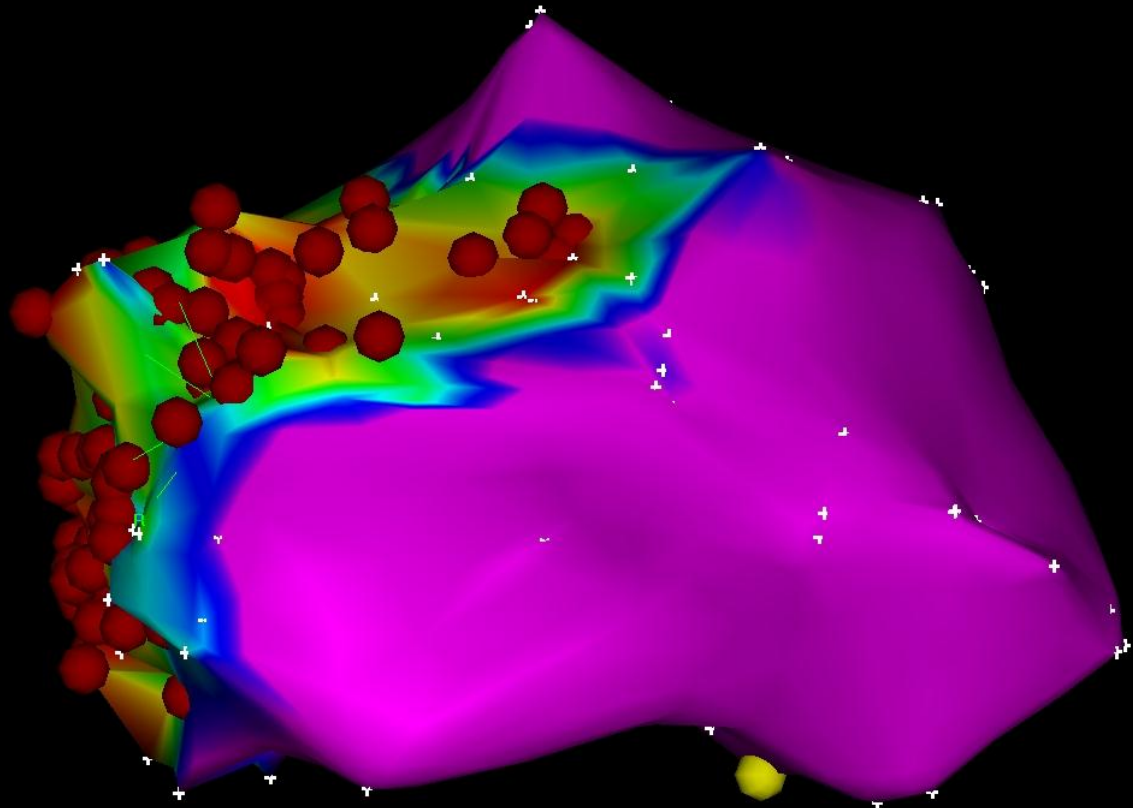


AP PA LAO RAO LL RL INF SUP

1-Map (216, 0)

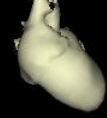

0.50 mV **Bi** 1.50 mV



1.00

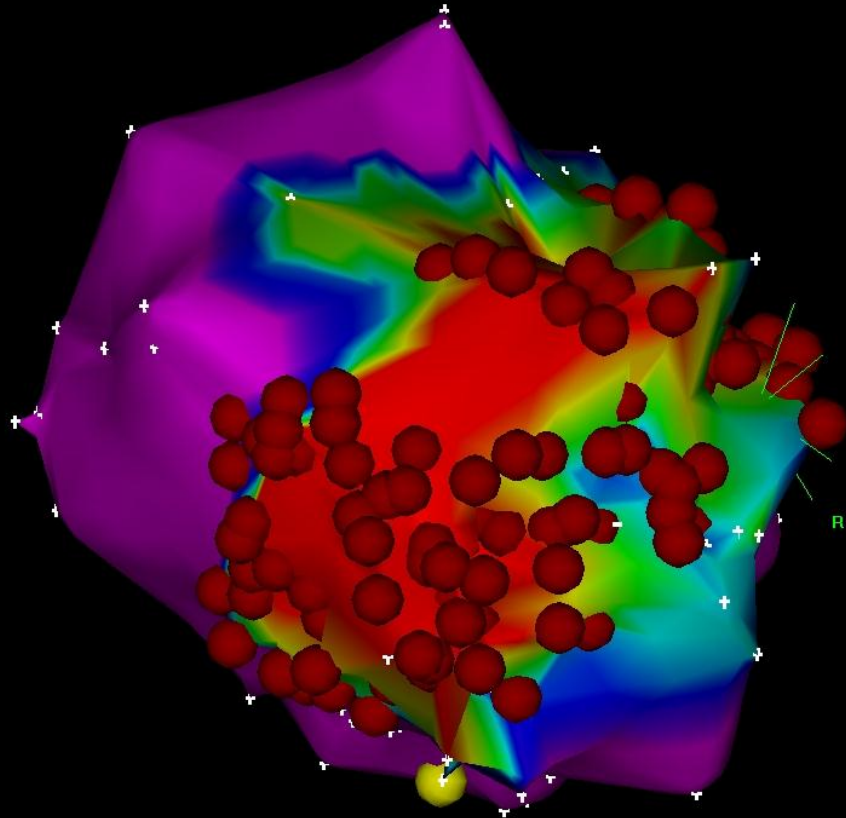
RAO



AP PA LAO RAO LL RL INF SUP

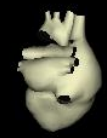1-Map (216, 0)

0.50 mV **BI** 1.50 mV



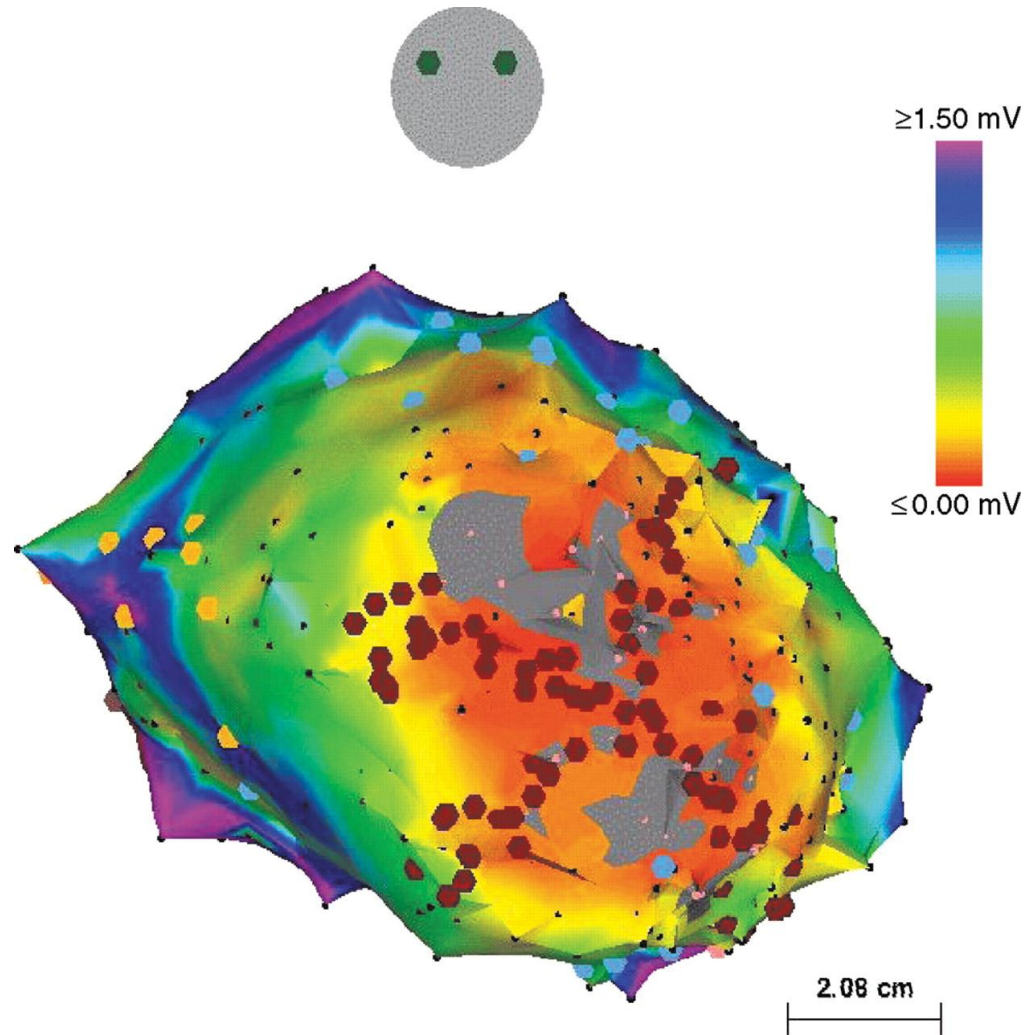
R

1.00

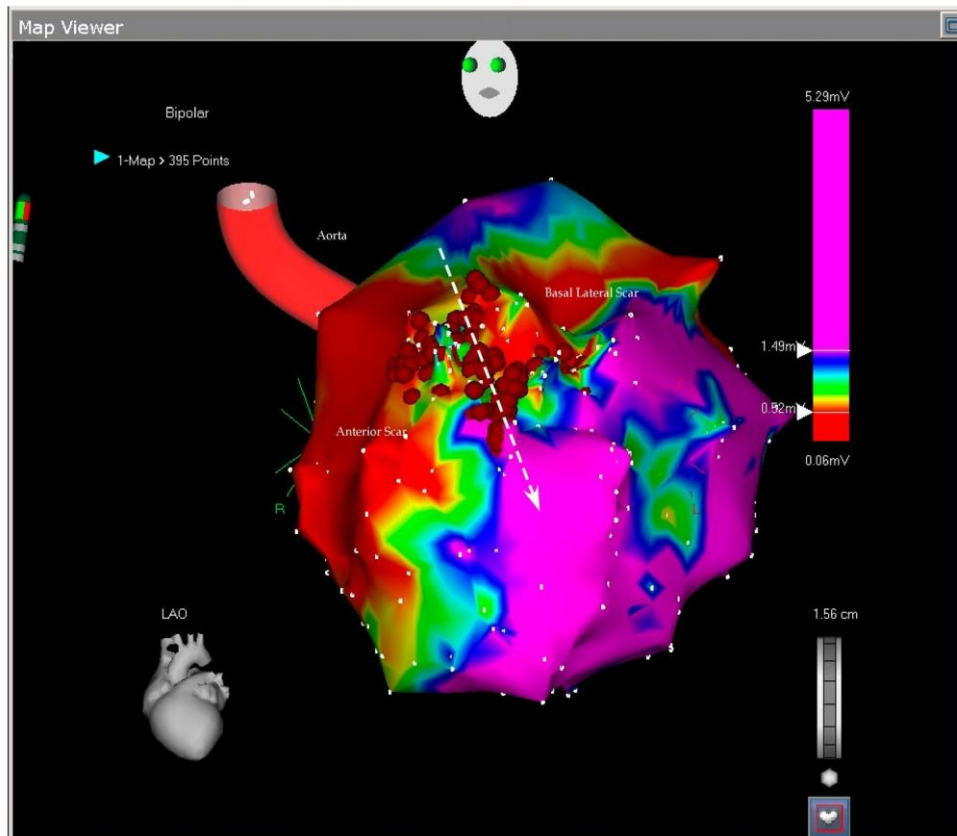


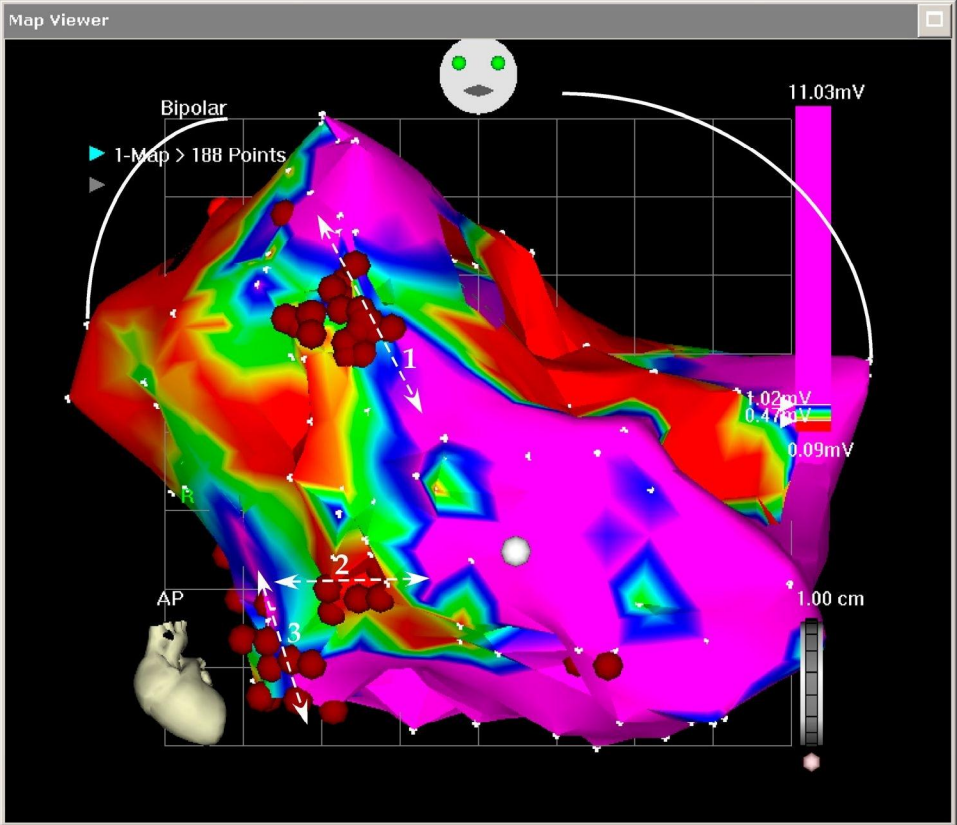
AP PA LAO RAO LL RL INF SUP

# Bipolar voltage map of the left ventricle (anteroposterior projection).

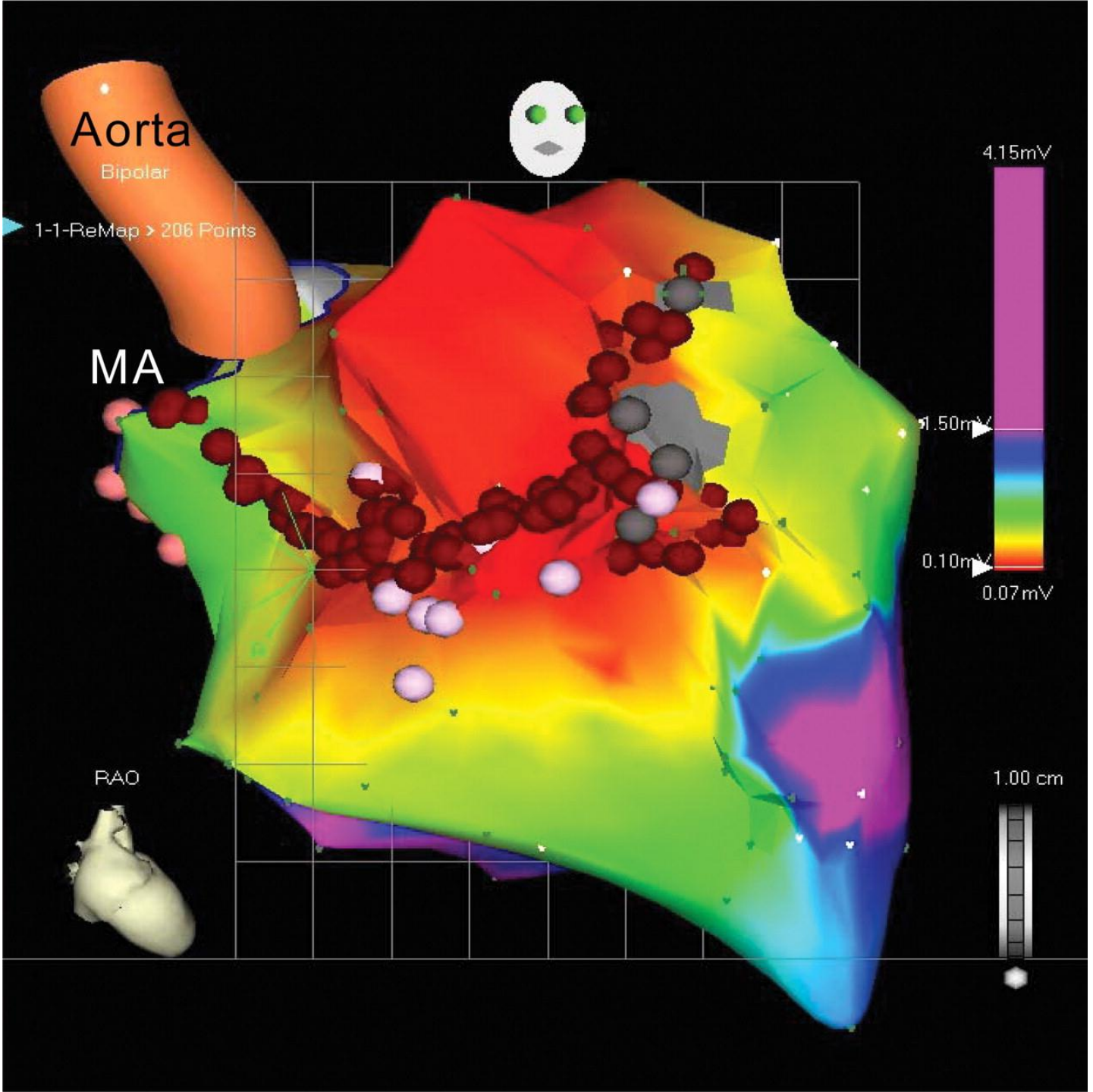


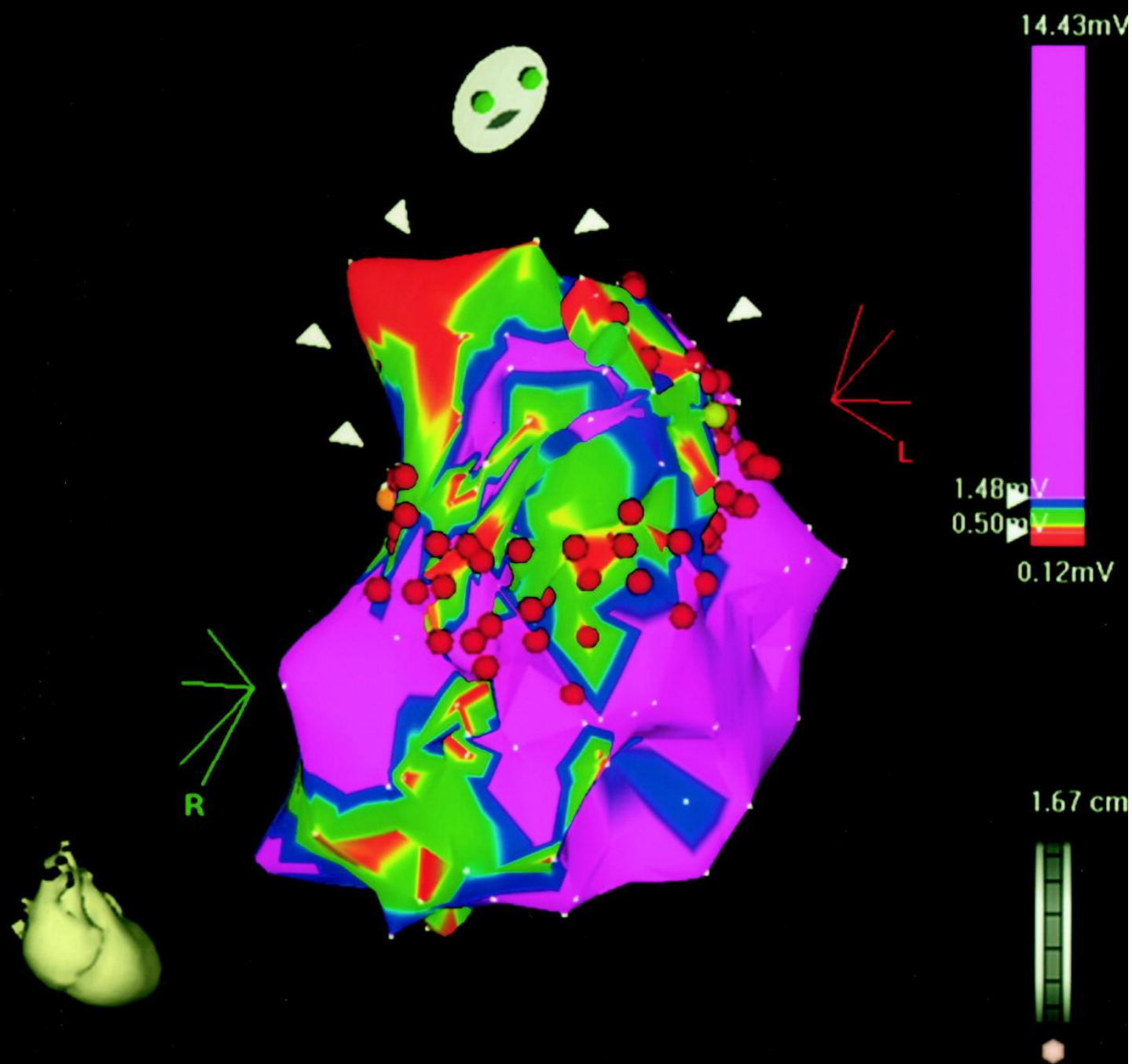
Volkmer M et al. *Europace* 2006;8:968-976





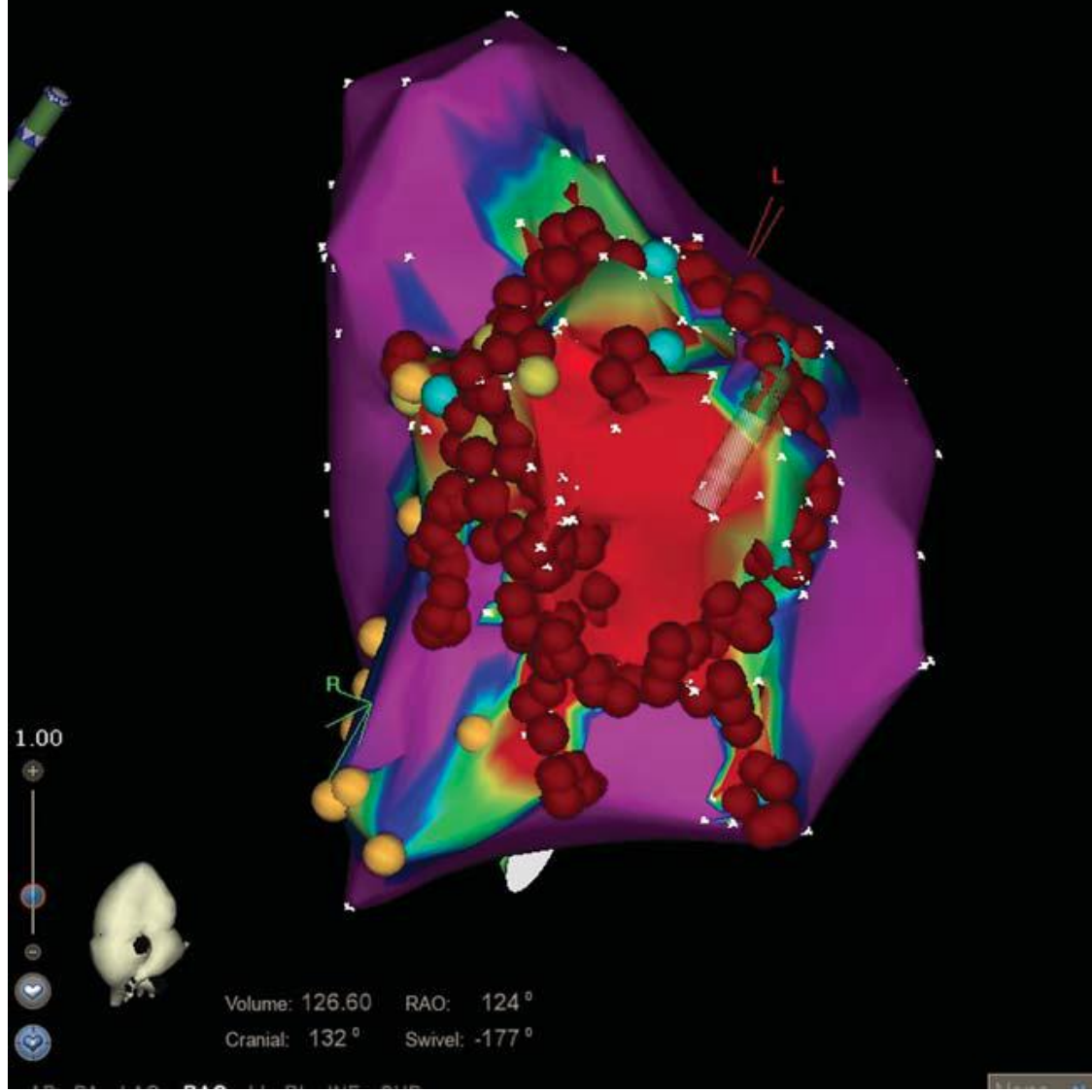


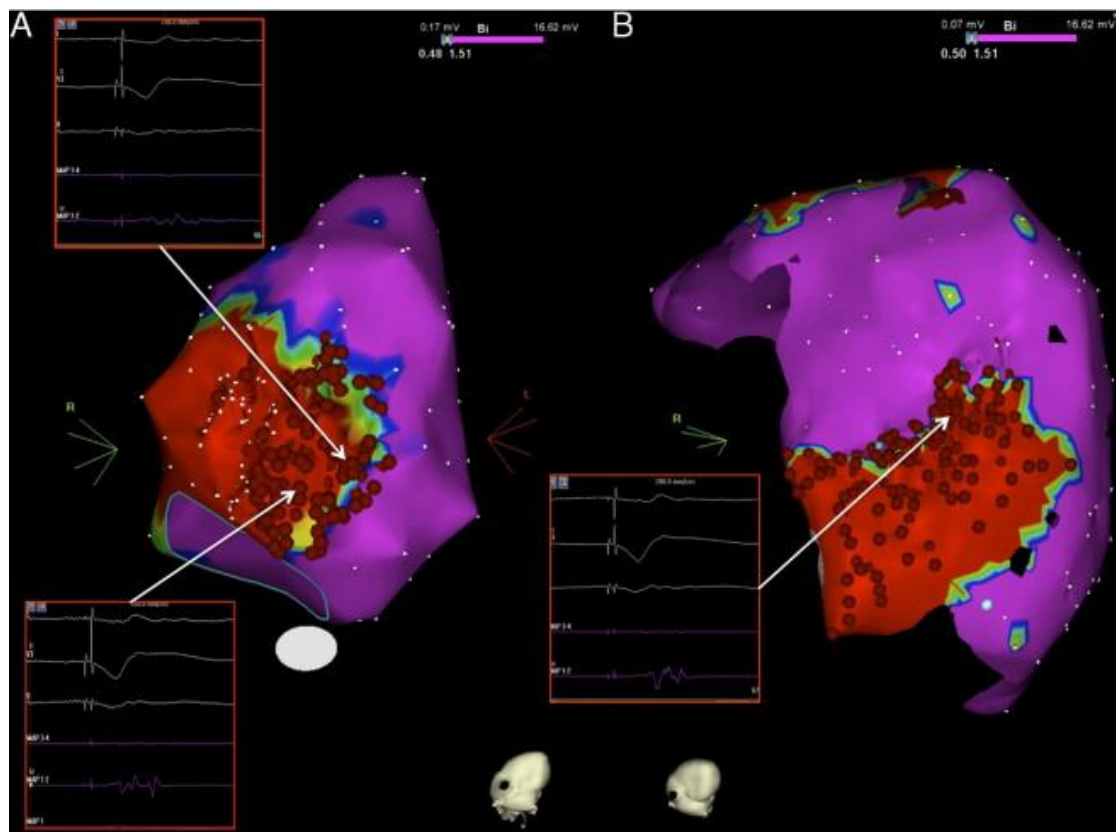


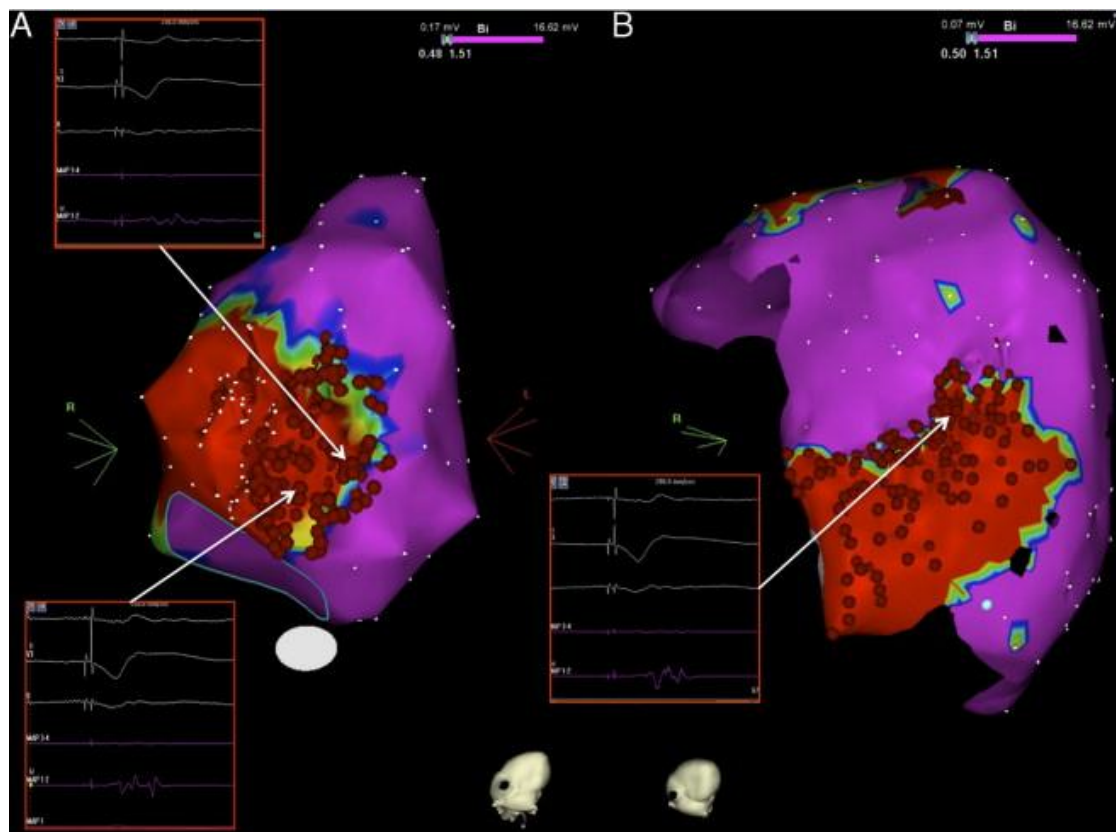


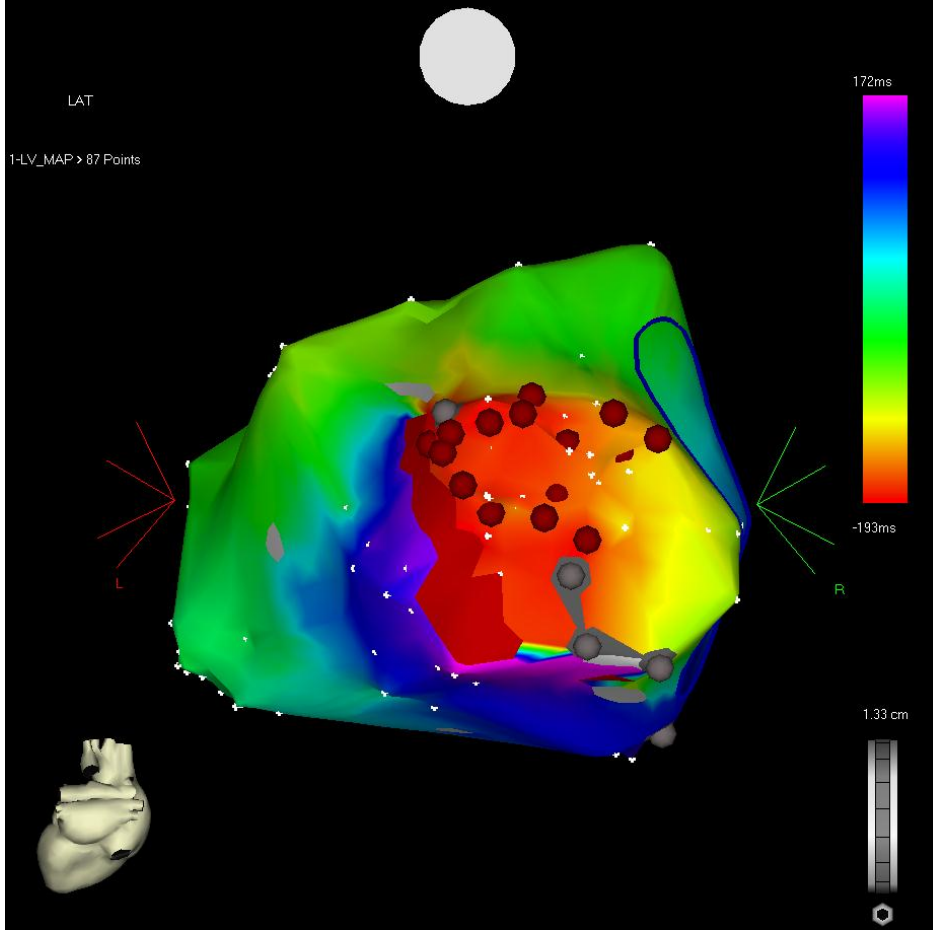
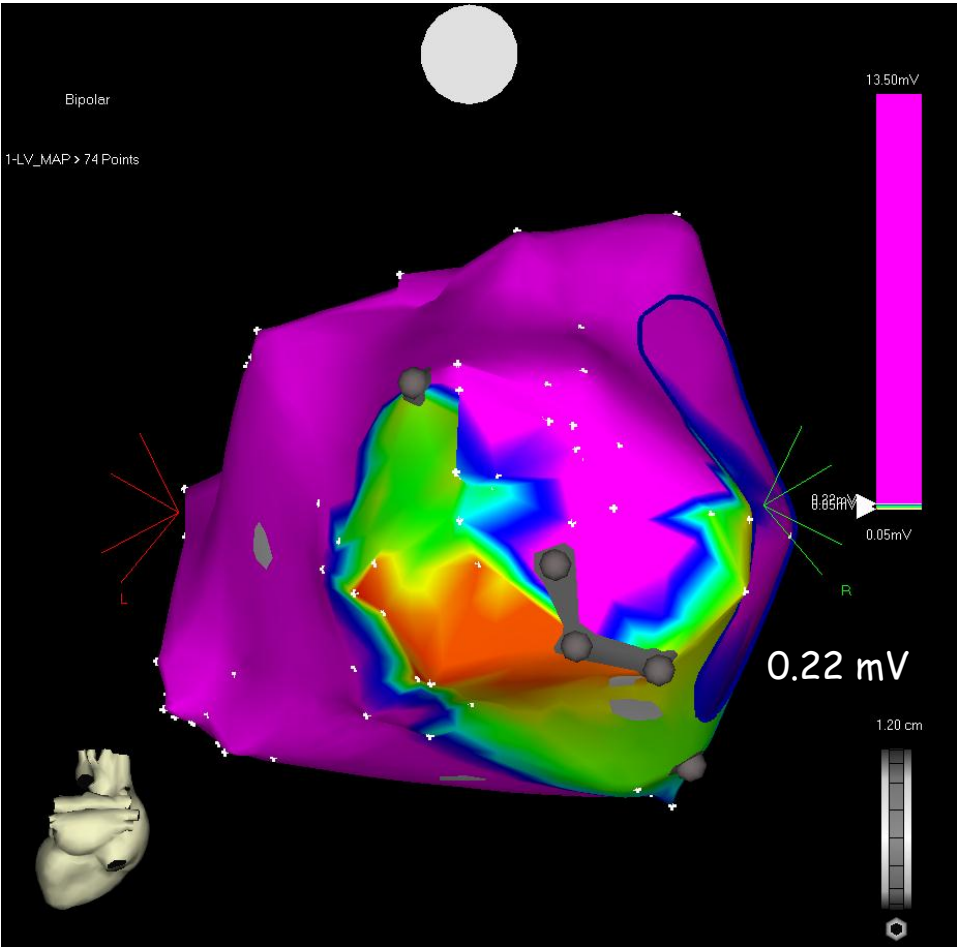
1-Map (423, 0)

0.02 mV Bi 27.07 mV  
0.36 1.54









# Substrat bazlı Post-Fallot VT Ablasyonu

